Check for updates

Head & Neck

WILEY

CLINICAL REVIEW

The Importance of Recognition and Management of Oral Lichen Planus: Navigating Epidemiology, Pathogenesis, Cancer Risk, and Advances in Management

Elahe Akbari[1] | Joel B. Epstein[2,3] | Firoozeh Samim[1]

[1]Faculty of Dental Medicine and Oral Health, McGill University, Montreal, Quebec, Canada | [2]City of Hoipe Comprehensive Cancer Center, Duarte, California, USA | [3]Cedars Sinai Health System, Los Angeles, California, USA

Correspondence: Firoozeh Samim (firoozeh.samim@mcgill.ca)

Received: 18 March 2025 | **Revised:** 15 July 2025 | **Accepted:** 4 August 2025

Funding: The authors received no specific funding for this work.

Keywords: etiology | management | oral lichen planus | oral potentially malignant disorder | risk factors

ABSTRACT

Background: Oral lichen planus (OLP) is a chronic inflammatory disorder classified as an oral potentially malignant disorder (OPMD) due to its association with an increased prevalence and a risk of progressing to oral squamous cell carcinoma (OSCC) of up to 5%.

Methods: We conducted a comprehensive literature review to update the epidemiology, etiology, pathogenesis, diagnosis, and management of OLP using PubMed and Web of Science databases up to April 2025.

Results: OLP is a T-cell-mediated disorder, with CD4+ and CD8+ T cells playing a key role in its pathogenesis. Its multifactorial nature involves genetics, infections, immune dysregulation, allergens, stress, autoimmune diseases, and medications. Treatment options include topical corticosteroids as the first-line therapy, along with systemic medications and emerging therapies that show promise in management.

Conclusions: Regular monitoring and early intervention are crucial due to OLP's malignant potential. Further research is needed to refine treatments and assess long-term efficacy.

1 | Introduction

Lichen planus is a chronic, immune-mediated inflammatory disease that can affect skin, hair, nails, eyes, and mucous membranes. The most typical clinical feature of this disease is white hyperkeratotic striae [1, 2]. The term "lichen planus" (LP) was first introduced by the British dermatologist Erasmus Wilson, recognized since 1866 [2–4].

The oral mucosa is the most frequently affected site by lichen planus, known as oral lichen planus (OLP), representing the most common immune-mediated oral mucosal condition. It occurs in 0.5%–2% of the population, predominantly affecting middle-aged females, and is rarely observed in children [1, 4]. OLP is characterized by remissions and flares, with various clinical presentations, including atrophic, erosive, bullous, plaque-like, and reticular forms. The gingiva, lateral and ventral tongue, and buccal mucosa are frequently affected by the reticular type, which manifests as lacy white striae. Red patches and ulcerations are the presentation of the atrophic and erosive types, respectively. While the rare bullous form of OLP appears with bullae or vesicles, resembling other oral immunobullous illnesses, plaque-form OLP presents as white plaques [5]. OLP is characterized by its potential to progress to oral squamous cell carcinoma (OSCC), which has led to its classification as an oral potentially malignant disorder (OPMD) after years of debate [6].

© 2025 Wiley Periodicals LLC.

The risk of malignant transformation to OSCC is estimated to be between 1% and 2% [4], with the World Health Organization (WHO) identifying several factors that elevate this risk, including female gender, the erosive form of OLP, and tongue involvement [6]. Therefore, the WHO recommends lifelong follow-up for patients with OLP to facilitate early cancer detection and identify those at greater risk. Various potential triggers of OLP have been identified, including gene polymorphisms, viral infections, systemic diseases, psychological stress, oral lichenoid hypersensitivity to dental restorative materials, vaccinations, and certain medications [2, 4].

The purpose of this review is to provide an overview of the current epidemiology of OLP, indications for management, and to provide an update on advances in management.

2 | Methods

Published data from this review were identified by a search and selection database of PubMed, Web of Science up to April 2025. In addition, gray literature was also screened on Google Scholar; and results obtained from this platform were cross-verified with other sources before inclusion to ensure relevance and quality. The search criteria were set as "oral lichen planus", "oral lichen planus pathogenesis", "oral lichen planus diagnosis", "oral potentially malignant disorder", "oral squamous cell carcinoma", and "management of oral lichen planus". Regarding the initial list of studies, the reference lists from relevant articles, reviews, and books on the subject were obtained. Furthermore, papers that cite the initial list of studies were also reviewed, which allowed us to include more recent studies that were based on prior published reports. A total of 137 studies were included, which were grouped based on the following topics: epidemiology, etiopathogenesis, clinical features, diagnosis, and treatment. Articles including non-English publications, case reports with fewer than five cases, studies with incomplete data or poor methodological quality, and those unrelated to OLP were excluded.

3 | OLP Epidemiology

The global prevalence of OLP is estimated to be 1.01%, with higher rates in South America at 1.74%, Africa at 1.43%, Europe at 1.32%, and lower in Asia at 0.83% and North America at 0.47% [7]. Among countries, Brazil had the highest prevalence at 6.04% [8], whereas India recorded the lowest prevalence at 0.49%. OLP risk increases significantly after the age of 40 [7], and women are more frequently affected than men [9]. Recent U.S. data show that LP prevalence increases with age, reaching 0.33% in those aged 70–79, and is 1.77 times more common in women than men [10]. Detection of OLP also varies based on clinician expertise, as oral medicine and pathology specialists reported a prevalence of 1.80% compared to dentists at 0.61% and dermatologists at 0.33% [7].

4 | OLP Pathogenesis

The immune-mediated response, driven by T cells primarily, defines the intricate pathophysiology of OLP. Antigen presentation by keratinocytes stimulates CD4+ helper T cells as well as CD8+ cytotoxic T cells, which in turn produce cytokines including IL-2, IFN-γ, and TNF-α which further induce cytotoxic T-cell proliferation and cause apoptosis of basal keratinocytes, producing the characteristic epithelial changes in OLP [11–14]. Indeed, activated CD4+ and CD8+ T cells, along with a high number of Langerhans cells expressing MHC class II and hence participating in further T-cell activation, are the main cells represented in the inflammatory infiltrate of OLP lesions [13]. Additionally, Th17 T cells and other cell types produce IL-17, which is essential for eliminating bacterial and fungal infections; it can also result in inflammation and tissue damage. As a result, it could be the cause of or a result of OLP surface erosions and ulcerations [12]. Moreover, the Th1/Th2 cytokine imbalance, with elevated Th1 cytokines, enhances $CD8^+$ cytotoxic T-cell activity, driving keratinocyte apoptosis [15]. Cytokine polymorphisms may influence whether lesions are confined to the oral cavity (IFN-γ associated) or in conjunction with skin lesions (TNF-α associated). Furthermore, dendritic cells, particularly plasmacytoid dendritic cells, produce IFN-α which can enhance cytotoxicity, activating natural killer/T cytotoxic cells or FasL-mediated apoptosis [11, 16]. Notably, IFN-γ exerts many of its effects through the JAK/STAT signaling pathway; binding to its receptor activates JAK1 and JAK2, which phosphorylate STAT proteins that translocate to the nucleus to promote transcription of genes like CXCL10. CXCL10 recruits T cells expressing CXCR-3 to the lesion site, amplifying the inflammatory response in a self-sustaining loop. This IFN-γ/ CXCL10 pathway is considered a key mediator in persistent inflammation in LP [17]. Chronic OLP is exacerbated by the activation of NF-κB and the inhibition of TGF-β signaling pathways, leading to keratinocyte hyperproliferation and epithelial hyperplasia, resulting in white lesion development [18]. OLP is ultimately characterized by tissue damage and prolonged inflammation due to a complex interaction between immunological dysregulation, overproduction of cytokines, and genetic factors (Figure 1).

5 | OLP Etiology

OLP is a multifactorial condition, with genetic predisposition as a significant factor in its development. Specific genes, including HLA-B8, -B51, -Bw57, and -Bw61, are commonly expressed in affected individuals [19]. Among the 132 genes implicated in OLP, a few key "leader genes," including JUN, EGFR, FOS, IL2, and ITGB4, have been identified as central to pathogenesis [20]. Viral infections also play a role, with several studies highlighting potential associations between OLP and infections like varicella-zoster (VZV), which is linked to linear LP and zosteriform LP [21]. Additionally, Epstein–Barr virus (EBV), a common herpes virus found in over 90% of the population, has been related to OLP [22], with studies showing a 35% positivity rate in OLP patients compared to none in controls [23]. Raybaud et al. indicated that EBV prevalence in OLP can be as high as 74%, particularly in erosive forms [24], while Vieira Rda et al. found EBV in 75% of saliva samples from OLP patients and in 64.7% of controls, but no significant differences in clinical variations based on sample type [25]. Thirty-three studies on human papillomavirus (HPV) detection in OLP reported widely varying rates, with Kato et al. finding a prevalence of 41.5% among OLP patients, mainly for high-risk genotypes 16 and 18 [26].

10970347, 0, Downloaded from https://onlinelibrary.wiley.com/doi/10.1002/hed.70012 by City Of Hope - Lee Graff Medic, Wiley Online Library on [26/08/2025]. See the Terms and Conditions (https://onlinelibrary.wiley.com/terms-and-conditions) on Wiley Online Library for rules of use; OA articles are governed by the applicable Creative Commons License

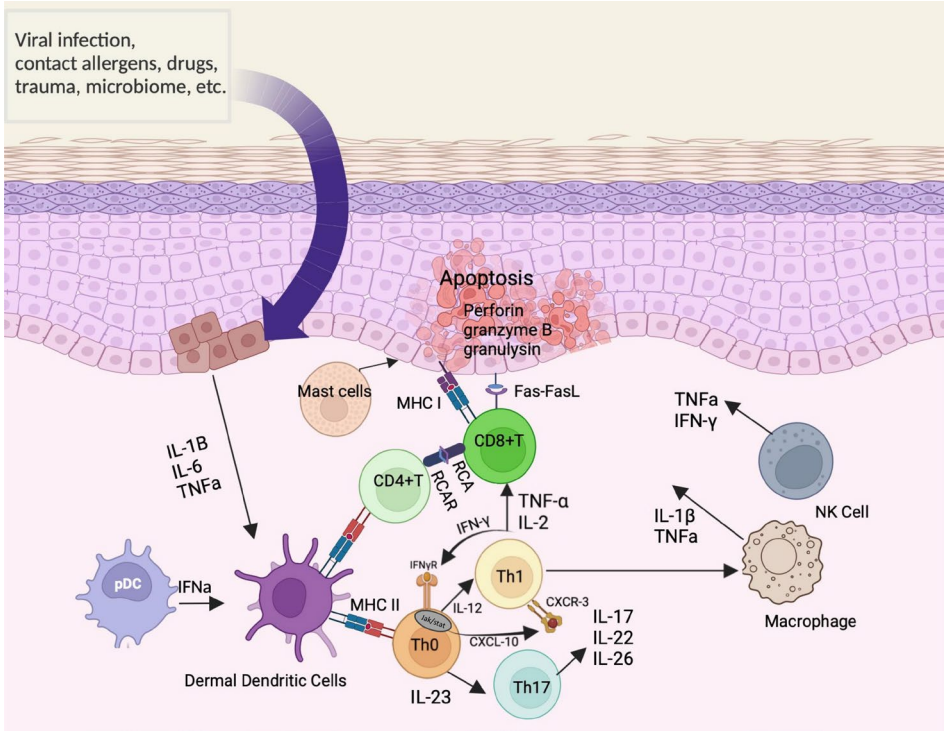

FIGURE 1 | Immunopathogenesis hypothesis of OLP. [Color figure can be viewed at wileyonlinelibrary.com]

A meta-analysis revealed that OLP patients have about seven times the odds of HPV infection compared to controls, with strong associations for HPV-16 and HPV-18, and indicated a higher prevalence of HPV in biopsies than in saliva samples [27]. Human herpesvirus 7 (HHV-7) and human herpesvirus 6 (HHV-6) have also been detected in infiltrating plasmacytoid dendritic cells within lesional skin biopsies [28, 29]. Another well-documented association is with hepatitis C virus (HCV), as LP patients are up to 13 times more likely to have HCV [30–32]. The exact mechanism is unclear but likely involves dysregulation, with CD8+ T lymphocytes specific to the virus found in LP lesions [33]. The recent COVID-19 pandemic has added another layer of complexity, with studies suggesting that COVID-19 infection or vaccination may trigger immune dysregulation, involving T-cell activation and cytokine production, potentially leading to OLP development [34–36]. A prospective observational study found that 12 out of 74 COVID-19 patients (16.2%) developed OLP. However, the lack of longitudinal follow-up and observational nature of the study underscores the need for cautious interpretation of these findings [37]. A retrospective cohort study using the TriNetX database compared 217 863 vaccinated patients to an equal number of unvaccinated patients. They found that 0.067% of vaccinated patients developed OLP within 6 days, compared to 0.027% in the unvaccinated control group. Although the risk was higher among vaccinated individuals, the overall incidence remains low, suggesting that these lesions are rare adverse events [38]. Liver health also influences OLP, with cytochrome P450 enzymes involved in metabolizing drugs that can induce or worsen the condition. Several retrospective studies proved an association between elevated serum aminotransferases and OLP lesions [39]. Furthermore, oral microbiota shifts are associated with OLP, potentially by triggering immune responses. Significant dysbiosis was found in OLP patients' saliva, with elevated levels of bacteria (Solobacterium, Fusobacterium, Porphyromonas, Prevotella), fungi (Candida, Aspergillus, Alternaria), and viruses, along with reduced levels of Streptococci, Actinobacteria, and Firmicutes compared to healthy controls [40, 41]. In addition to microbial factors, OLP can be triggered by contact allergens like dental materials, including amalgam, composite resins, nickel, and gold [42, 43]. Studies have shown that stress, whether physical or psychological, can suppress the immune response through the release of catecholamines and cortisol, which in turn activate inflammatory cytokines such as TNF-alpha, IL-1-alpha, IL-6, and IL-8 [2, 44, 45]. Additionally, anxiety and depression are more common in OLP patients compared to controls, and exacerbations often coincide with anxiety episodes [2, 12]. Moreover, OLP patients are more likely to have comorbidities, including autoimmune diseases such as Sjögren syndrome, systemic lupus erythematosus (SLE), and ulcerative colitis [46–48]. A positive correlation with alopecia areata, vitiligo, and thyroid diseases (especially Hashimoto's thyroiditis) has also been confirmed [2, 49–51]. Additionally, LP is associated with a higher prevalence of obesity, dyslipidemia, diabetes, and metabolic syndrome due to chronic inflammation [52–55]. Oral Lichenoid Reactions (OLRs) are associated with various external triggers, including contact hypersensitivity to dental restorative materials (e.g., amalgam, gold, nickel), adverse reactions to certain medications, and systemic conditions such as graft-versus-host disease [56]. While OLP and OLR are clinically and histologically similar, certain distinguishing features can aid in diagnosis. Clinically, OLR lesions are often asymmetrical and localize adjacent to the offending agent, while OLP lesions are typically bilateral and symmetrical.

Histopathologically, OLRs tend to show more eosinophils, plasma cells, granulocytes, and a higher number of degranulated mast cells, while OLP is characterized by "saw-tooth" rete pegs, atrophic epithelium, and more intact subepithelial mast

10970347, 0, Downloaded from https://onlinelibrary.wiley.com/doi/10.1002/hed.70012 by City Of Hope - Lee Graff Medic, Wiley Online Library on [26/08/2025]. See the Terms and Conditions (https://onlinelibrary.wiley.com/terms-and-conditions) on Wiley Online Library for rules of use; OA articles are governed by the applicable Creative Commons License

cells [56–58]. These subtle differences combined with comprehensive clinical history and examination remain essential for diagnosis (Table 1).

6 | Why Treating OLP Is Important?

Treating OLP is crucial for improving patients' quality of life, as the condition can cause significant discomfort and functional impairment. OLP commonly affects the tongue, lips, gingiva, and buccal mucosa, presenting as fine white lines forming a lace-like pattern known as Wickham's striae, a pathognomonic characteristic of OLP [59].

Symptoms vary in intensity, including oral discomfort, roughness, and burning sensations, especially in erosive forms [60]. This persistent burning or tingling is often aggravated by factors such as sharp cusps, ill-fitting dentures, poor oral hygiene, chronic cheek biting, and consumption of spicy, acidic, or hot foods [3, 4, 61]. Xerostomia associated with OLP may further contribute to discomfort, dysphagia, halitosis, and increased caries risk. Additionally, lichenoid gingival inflammation can complicate periodontal status and accelerate attachment loss [4, 60]. Altered taste (dysgeusia), often described as a metallic or bitter sensation, can also affect food enjoyment [60]. Plaque and calculus buildup can aggravate OLP, increasing the risk of gingival recession and periodontal disease progression [62]. Post-inflammatory pigmentation may present as diffuse brown or black patches [63]. In severe cases, extensive lesions can impair speech, and the chronic discomfort associated with OLP can negatively impact daily activities, contributing to psychological distress, including anxiety and depression [60].

Beyond symptom management, OLP requires careful monitoring due to its potential for malignant transformation. In 2005, the WHO classified OLP as an OPMD due to its potential to progress to OSCC, with malignancy ratios ranging from 0.44% to 2.28% [6]. However, a recent meta-analysis updated the malignancy ratio to 1.43%, highlighting that OLP cases with epithelial dysplasia had a significantly higher rate of 5.13% [64]. This progression involves genetic and cellular changes, including reduced levels of succinate dehydrogenase enzyme B (SDHB) and DNA damage caused by inducible nitric oxide synthase (iNOS), leading to the accumulation and mutation of the p53 protein, a key marker observed in both OLP and OSCC cases [65, 66]. Patients with OLP and HCV have a 3.16 times higher risk of malignancy, with additional risk factors including female gender, older age, erosive forms, smoking, and alcohol consumption [67, 68]. The mean interval between OLP diagnosis and cancer diagnosis varies significantly, ranging from 20.8 months to

TABLE 1 | Triggering and exacerbating factors of OLP/OLR.

Medications	**Viruses**	**Nutrition Deficiencies**	**Allergy**
Beta-blockers	- Varicella-Zoster Virus	- Vitamin D	- Food
ACE inhibitors Diuretics	- Epstein-Barr Virus	- Vitamin B12	- Metals
Antihypertensives	- Human Papilloma Virus	- Folic Acid	- Dental Amalgam
- Hydrochlorothiazide	- Human Herpesvirus 6	- Iron	- Composite Resins
NSAIDs	- Human herpesvirus 7	- Vitamin A, C, and E	- Nickel
-	- Hepatitis C Virus	**Vaccines**	- Gold
Antibiotics	- Hepatitis B Virus	**Covid-19 Vaccines**	**Trauma**
- Tetracycline	- Coronavirus SARS-CoV-2	- Tozinameran	- Rough dental surfaces
- Sulfamethoxazole	**Systemic Diseases**	- Spikevax	- Severe Attrition
Anticonvulsants	- Hypertension	- Vaxzevria	- Decreased Vertical Dimension
- Carbamazepine	- Diabetes	- Jcovden	**Lifestyle**
Antifungals	- Dyslipidemia	**Hepatitis A and B Vaccines**	- Obesity
- Ketoconazole	- Thyroid disease	- HAVRIX	- Stress
Antimalarials	- Liver dysfunction	- ENGERIX-B	- Insomnia
- Chloroquine	- Graft versus host disease	**Influenza Vaccines**	- Betel Quid Chewing
Antiretrovirals	**Autoimmune Diseases**	**Herpes Zoster Vaccines**	
- Zidovudine	- Sjogren syndrome	**Covid vaccines**	
Antituberculosis drugs	- Systemic lupus erythematosus	**Oral Factors**	
- Ethambutol	- Mixed connective tissue disorder	- Oral Microbiome	
- Pyrazinamide	Myasthenia Gravis	- Salivary Gland Hypofunction	
- Isoniazid	- Ulcerative Colitis	**Genetic Predisposition**	
- Rifampicin	- Alopecia Areata		
Glycemic drugs	- Vitiligo		
- Tolbutamide	**Bone Marrow Transplant**		
- Glipizide	-Graft-versus-host disease		
- Insulin			
Statins			
- Pravastatin			
Chemotherapy			
- Immune check point inhibitors			

10970347, 0, Downloaded from https://onlinelibrary.wiley.com/doi/10.1002/hed.70012 by City Of Hope - Lee Graff Medic, Wiley Online Library on [26/08/2025]. See the Terms and Conditions (https://onlinelibrary.wiley.com/terms-and-conditions) on Wiley Online Library for rules of use; OA articles are governed by the applicable Creative Commons License

10.1 years, with the highest risk occurring between 3- and 6-year post-diagnosis [69]. Infectious factors, such as *Fusobacterium nucleatum* and *Candida albicans*, have been implicated in malignant transformation due to their potential production of carcinogenic compounds [70, 71].

Given these risks, regular long-term follow-up is crucial for early detection of OSCC. Follow-up intervals may range from every 2 months to annually, with annual assessments advised for reticular OLP. However, patients with dysplastic OLP should be examined more frequently, potentially every 2–3 months or if a change in symptoms is noted. If erosive changes are observed, additional biopsies may be required, and follow-up intervals should be reduced [72]. Biomarkers such as Podoplanin and ABCG2 have shown promise as risk indicators [4, 73]. Additionally, cell cycle regulators, intercellular adhesion proteins, and apoptotic biomarkers including p53, p63, and p73, serve as potential markers for the early detection of malignant transformation in OLP [74].

7 | OLP Treatment

7.1 | Corticosteroids

Corticosteroids, synthetic analogs of cortisol, are the gold standard for treating OLP due to their anti-inflammatory and immunosuppressive effects [75]. Topical glucocorticosteroids, such as triamcinolone acetonide, fluocinonide, betamethasone, and clobetasol propionate, are the first line of treatment for mild to moderate OLP lesions. High potency steroids are often required due to limited oral mucosal contact time, and if involving keratinized mucosa, such as gingivae [76]. These are typically applied as gels, creams, or rinses, as ointments are not suitable for mucosal surfaces. Topical therapies are preferred for their ability to provide local effects with minimal systemic absorption [77]. Beyond symptom management, recent research suggests that management using topical corticosteroid therapy may delay OLP's malignant transformation to OSCC by 4 years [78].

Budesonide, a high-potency topical steroid that can be compounded leading to minimize systemic effects, but prolonged use may still cause mucosal thinning, telangiectasia, and candidiasis [2, 3, 79], as Ku et al. found microbial composition changes after 4 weeks of 0.05% dexamethasone mouthwash use; potentially increasing the risk of fungal infections [80].

Systemic corticosteroids, such as prednisone and methylprednisolone, are reserved for severe, widespread, or recalcitrant cases of OLP that do not respond to topical treatments [81]. While effective, they pose risks such as adrenal suppression, iatrogenic Cushing's syndrome, hyperglycemia, osteoporosis, hypertension, and immunosuppression [77, 82]. Prolonged use (over 2 weeks) requires tapering to avoid adrenal suppression and potential adrenal crisis [3]. A thorough medical history is essential, as these drugs are contraindicated in patients with conditions such as stomach ulcers, diabetes, or hypertension [2, 83]. In such refractory or contraindicated cases, nonsteroidal agents like mycophenolate mofetil, sirolimus, or calcineurin inhibitors may be considered, though calcineurin inhibitors may carry a carcinogenic risk [84, 85]. Intralesional steroids like triamcinolone acetonide can target localized ulcerations with fewer systemic effects but may cause pain and tissue atrophy [77].

7.2 | Immunosuppressants

Immunosuppressive drugs, including tacrolimus, dapsone, cyclosporine, azathioprine, and pimecrolimus, play a significant role in managing OLP by inhibiting T lymphocyte function and reducing inflammation [4, 77, 86]. Tacrolimus (0.1% ointment, twice daily for up to 4 weeks) is effective for erosive OLP but may cause transient burning, relapse after cessation, and is difficult to apply to mucosa [77, 87]. Pimecrolimus cream is more mucosa-friendly and easier to apply. Dapsone (50–150 mg/day for up to 6 months) has steroid-comparable efficacy but may cause headaches and hemolysis [4, 77]. Azathioprine offers immunosuppressive and anti-inflammatory benefits but carries risks of bone marrow suppression and liver dysfunction [88]. Cyclosporine, though useful for persistent OLP and available in compounded topical forms, is limited by systemic side effects (e.g., hypertension, gingival hyperplasia) and is ineffective as a mouthwash due to enzymatic deactivation [14]. Although effective, these immunosuppressants can cause side effects such as bad taste, nephrotoxicity, and high costs, requiring careful monitoring under specialist supervision [89].

7.3 | Retinoids

Since retinoid deficits can lead to keratinization of the oral mucosa, retinoid metabolites, which are derived from vitamin A, are used topically and systemically in the treatment of OLP. Retinoids are needed for the normal growth and proliferation of epithelial cells [90]. Common topical retinoids, including tretinoin, isotretinoin, fenretinide (0.1% gel), and tazarotene, have demonstrated efficacy in reducing reticular and plaque lesions while lowering the likelihood of recurrence post-treatment. In contrast, systemic retinoids, such as etretinate, isotretinoin, acitretin, temaroten, and tretinoin, are less frequently prescribed due to potential side effects including liver damage, teratogenicity, and cheilitis. However, temaroten can efficiently treat OLP with fewer adverse effects [4, 77, 91].

When gingival sites or palatal mucosa are involved, an enhanced effect can be achieved using occlusive vinyl appliances (medication trays) by increasing contact time and reducing the dilution of topical anti-inflammatory agents.

7.4 | Phototherapy

Photochemotherapy, particularly PUVA therapy with the photosensitizer psoralen, has proven effective in treating resistant OLP and skin LP [77]. UVA treatment without photosensitizers led to significant improvement in 87% of OLP patients; controlled studies have confirmed the efficacy of systemic psoralen for severe cases. However, side effects like nausea, dizziness, ocular symptoms, paresthesia, and oncogenic potential restrict its use to severe, unresponsive cases [92]. A study using ultraviolet B phototherapy with the TheraLight U 120-2 system in 14 patients showed promising results, with nine achieving full

10970347, 0, Downloaded from https://onlinelibrary.wiley.com/doi/10.1002/hed.70012 by City Of Hope - Lee Graff Medic, Wiley Online Library on [26/08/2025]. See the Terms and Conditions (https://onlinelibrary.wiley.com/terms-and-conditions) on Wiley Online Library for rules of use; OA articles are governed by the applicable Creative Commons License

remission and continued benefits for 29 weeks during maintenance treatment [93].

7.5 | Laser Treatment

Laser therapy has emerged as a promising option for treating OLP, particularly for its anti-inflammatory and antimicrobial properties [94]. CO_2 lasers, known for their thermal impact, effectively manage erosive and atrophic OLP by carbonizing and vaporizing tissue, closing blood vessels, and sterilizing incisions, making them useful in severe cases [86]. Nd: YAG lasers, with deep tissue penetration, not only provide significant pain relief but also improve clinical symptoms and control fungal strains like *Candida albicans* [95]. Additionally, Er: YAG lasers have proven effective in reducing microbial loads, such as *Porphyromonas gingivalis*, which are often elevated in OLP patients [96].

Low-level laser therapy (LLLT) now known as photobiomodulation (PBM), using varying wavelengths (400–1.100 nm), has shown promise, particularly in enhancing cell metabolism without damaging tissues [77]. While some studies report PBM's ability to reduce pain and achieve lesion resolution, three studies showed significantly better improvement with topical corticosteroids compared to LLLT, with only one study demonstrating notable lesion improvement using LLLT [97, 98]. Despite these mixed results, PBM remains a viable alternative, especially for atrophic-erosive OLP, with potential analgesic, anti-inflammatory effects, and wound healing; though the lack of a standardized clinical protocol limits widespread adoption.

7.6 | Photodynamic Therapy

Photodynamic therapy (PDT) has an impact on OLP treatment as a new non-invasive method. It uses photosensitizers like methylene blue (MB) or toluidine blue (TB) and light to induce cell damage and lower inflammation [99]. Clinical studies indicate that PDT can alleviate pain and minimize lesions, demonstrating comparable effectiveness to topical corticosteroids and dexamethasone mouth rinse in treating OLP [100]. For example, a clinical study by Fatemeh et al. treated 11 OLP patients comparing TB-mediated PDT and topical corticosteroids. PDT was more effective up to day 21, but after 4 weeks of corticosteroid treatment on both sides, outcomes were similar. The authors suggest PDT can shorten treatment duration and serve as an adjuvant for resistant or recurrent OLP [101]. Furthermore, PDT appears to be a safe alternative or additional intervention for patients with comorbid conditions such as diabetes and hypertension [102]. However, despite its potential, the current evidence base is limited by considerable heterogeneity across studies. Variations in photosensitizer type (e.g., MB, 5-aminolevulinic acid, chlorin e6, TB), application duration, light source (diode lasers, xenon arc lamps, LEDs), wavelength (typically 600–660 nm), energy density, and treatment frequency impede standardization [99, 100, 102, 103]. Differences in lesion selection, outcome measures, and clinical type (e.g., erosive vs. reticular) further limit direct comparisons and may impact reproducibility. Additionally, while PDT has known antimicrobial effects, its ability to disrupt deeper, more resistant biofilms remains unclear [103]. Recurrence rates are also poorly documented due to short follow-up periods, and subgroup analyses are often underpowered due to small sample sizes [100]. Therefore, while PDT demonstrates promising potential, its long-term efficacy, optimal treatment parameters, and impact on recurrence rates require further validation through larger, well-designed, and multi-center clinical trials.

7.7 | Hydroxychloroquine

Hydroxychloroquine (HCQ) has been investigated as a treatment option for OLP, particularly in refractory cases. A 1993 study reported a 90% response rate in 10 patients with erosive OLP treated with HCQ monotherapy [104]. Significant lesion reduction (63.3%) and pain relief were observed with a topical HCQ noisome gel in a placebo-controlled trial [105]. Other studies have reported more than 80% improvement [106], and moderate-to-marked improvement in 57% of patients [107]. A prospective study demonstrated a decrease in regulatory T cells after 2 weeks of HCQ use, suggesting an immunomodulatory mechanism [108], while a retrospective study also noted reduced pain and disease severity in recalcitrant cases [109]. Despite these promising results, most studies were limited by small sample sizes, retrospective designs, and lack of standardized outcomes. However, a recent multicenter randomized controlled trial (RCT) confirmed HCQ's safety and efficacy, demonstrating comparable outcomes to topical dexamethasone [110]. Nonetheless, HCQ is not the preferred treatment due to the risk of lichenoid reactions and potential side effects such as retinal damage and hyperpigmentation with long-term use [107, 111]. Although HCQ shows antibacterial, antiviral, and antifungal properties, including activity against *A. fumigatus* and *A. nidulans*, its impact on *Candida albicans* in the oral cavity remains unstudied [112].

7.8 | Platelet-Rich Fibrin

Platelet-Rich Plasma (PRP) and its advanced form, injectable Platelet-Rich Fibrin (i-PRF), have shown promising potential in managing OLP [113]. PRP is derived from autologous platelet concentrates (APCs) created by centrifuging venous blood, resulting in a fibrin clot that contains platelets and white blood cells [114]. These biocompatible products deliver high concentrations of growth factors and cytokines, promoting tissue repair and reducing inflammation, thereby providing effective pain relief for OLP symptoms [115]. Unlike corticosteroids, which can lead to adverse effects such as mucosal atrophy, PRP and i-PRF present safer alternatives with fewer side effects. Although the initial response to PRP may be slower compared to corticosteroids, its long-term outcomes are often comparable, making it suitable for patients unresponsive to conventional therapies [113, 116]. I-PRF, identified in 2001, offers advantages over traditional PRP, including faster wound healing, enhanced immune response, and the absence of anticoagulants [117]. Recent studies, including a meta-analysis by Gupta et al., have indicated that local injections of i-PRF can effectively reduce pain and lesion size, with

10970347, 0, Downloaded from https://onlinelibrary.wiley.com/doi/10.1002/hed.70012 by City Of Hope - Lee Graff Medic, Wiley Online Library on [26/08/2025]. See the Terms and Conditions (https://onlinelibrary.wiley.com/terms-and-conditions) on Wiley Online Library for rules of use; OA articles are governed by the applicable Creative Commons License

outcomes similar to established treatments like triamcinolone acetonide. Specifically, findings from these studies highlight that i-PRF not only alleviates pain but also improves overall patient satisfaction due to its regenerative properties and minimal adverse effects [118].

7.9 | Curcumin

Curcumin, an extract from turmeric (*Curcuma longa*), is gaining attention as a potential adjunctive therapy for OLP due to its reported anti-inflammatory, antioxidant, and anti-carcinogenic properties. Historically used in traditional Indian medicine, some studies suggest curcumin may help alleviate symptoms in OLP patients, such as pain reduction and lesion improvement [119]. A systematic review described positive outcomes in trials using oral dosages of 300–600 mg three times daily for 8–12 weeks [120]. A study by Chainani-Wu et al. demonstrated that high-dose curcuminoids (6000 mg/day) can reduce OLP symptoms. However, the small sample size limited the statistical power, particularly in assessing inflammatory markers like CRP and IL-6 [121]. Additionally, in a 2015 study by Kia et al., the efficacy of 5% curcumin was compared with 0.1% triamcinolone, with complete pain resolution observed in 36% of the curcumin group and 32% of the triamcinolone group; however, the difference was not statistically significant [122]. Despite these findings, conflicting evidence exists as a study found no significant effect of curcumin on OLP [123], and other researchers have raised doubts about its overall efficacy in treating the condition [124].

7.10 | Hyaluronic Acid

Hyaluronic acid (HA) has shown potential as an effective treatment for OLP, particularly for short-term symptom relief. In a RCT of 50 patients with erosive OLP, those treated with 2% HA experienced significant reductions in pain (VAS score 1.48 vs. 7.76) and erythema (0.48 vs. 1.35) compared to the placebo group [125]. Furthermore, studies comparing HA gel to triamcinolone found both treatments equally effective in reducing pain and lesion size [126]. Though HA has demonstrated benefits in localized, short-term applications, its long-term effectiveness for OLP management remains uncertain.

7.11 | Vitamin D

Vitamin D is emerging as a valuable supplementary treatment in managing OLP due to its immunomodulatory and anti-inflammatory properties. Systematic reviews indicate that vitamin D supplementation, especially when combined with steroid therapies, significantly improves OLP symptoms compared to placebos or steroids alone. This is likely due to its regulation of keratinocyte proliferation and differentiation, which are crucial for mucosal health. Studies have found that patients receiving vitamin D, with or without psychological counseling, show significant improvements in symptoms [127]. A larger study involving 450 OLP patients also revealed that those supplemented with vitamin D experienced notable benefits [128].

7.12 | Periodontal Treatment

Oral care plays a crucial role in managing OLP, especially considering its intricate relationship with chronic periodontitis (CP), the leading cause of tooth loss in adults driven by bacterial infection and immune responses. Key risk factors for OLP progression, such as poor oral hygiene, stress, and dietary habits, emphasize the importance of periodontal health in OLP management [129]. Studies indicate a mutually reinforcing effect between OLP and CP, with significant improvements in OLP lesions observed following periodontal treatment [130]. Moreover, systemic risk factors like smoking, diabetes, and obesity can exacerbate both periodontal and OLP conditions. Smoking enhances inflammatory responses in OLP lesions and may increase cancer risks due to reduced macrophage expression [131]. Therefore, maintaining proper oral health is essential to reduce the severity of OLP lesions. Future attention to the oral microbiome is needed. Patients should avoid abrasive toothpaste and hard-bristle toothbrushes to minimize discomfort, and any restorations or appliances irritating should be adjusted. While asymptomatic patients with reticular OLP may not require treatment, erosive and atrophic forms necessitate intervention, and all forms of OLP require follow-up [85]. Addressing both the disease state and patient behaviors is vital for effective recovery.

7.13 | Surgery

OLP is an immune-mediated disorder, meaning that surgical excision and cryosurgery, which physically remove lesions without targeting the underlying immune processes, do not provide effective long-term management. As a result, lesions frequently recur after surgery. Cryosurgery often results in recurrence, with new lesions forming on healing wounds and more intense symptoms during the recovery process. Gingival grafts and free soft tissue grafts have also been utilized to treat localized erosive OLP lesions and may have a limited role in OLP-associated gingival recession [4].

The primary goal of OLP treatment is to reduce local inflammation, prevent recurrence, and reduce the potential for malignant transformation [132, 133]. Early detection of malignant progression is critical. Asymptomatic reticular lesions typically require only monitoring for changes. Management, therefore, should focus on treating atrophic and erosive lesions, alleviating symptoms, and minimizing the risk of cancer (Figure 2).

8 | Cost-Effectiveness and Accessibility Considerations

Optimal OLP therapies should be cost-efficient, effective, and have low toxicity. A systematic review compared efficacy and costs of available interventions used to treat OLP by analyzing 70 randomized clinical trials; it found that clobetasol remains the preferred option over fluocinonide, triamcinolone, and tacrolimus, due to its efficacy and lower cost (~$4.12–4.54/g vs. tacrolimus at $4.96/g) [134]. A pilot trial also demonstrated that both 0.1% tacrolimus and 0.05% clobetasol in orabase formulations

10970347, 0, Downloaded from https://onlinelibrary.wiley.com/doi/10.1002/hed.70012 by City Of Hope - Lee Graff Medic, Wiley Online Library on [26/08/2025]. See the Terms and Conditions (https://onlinelibrary.wiley.com/terms-and-conditions) on Wiley Online Library for rules of use; OA articles are governed by the applicable Creative Commons License

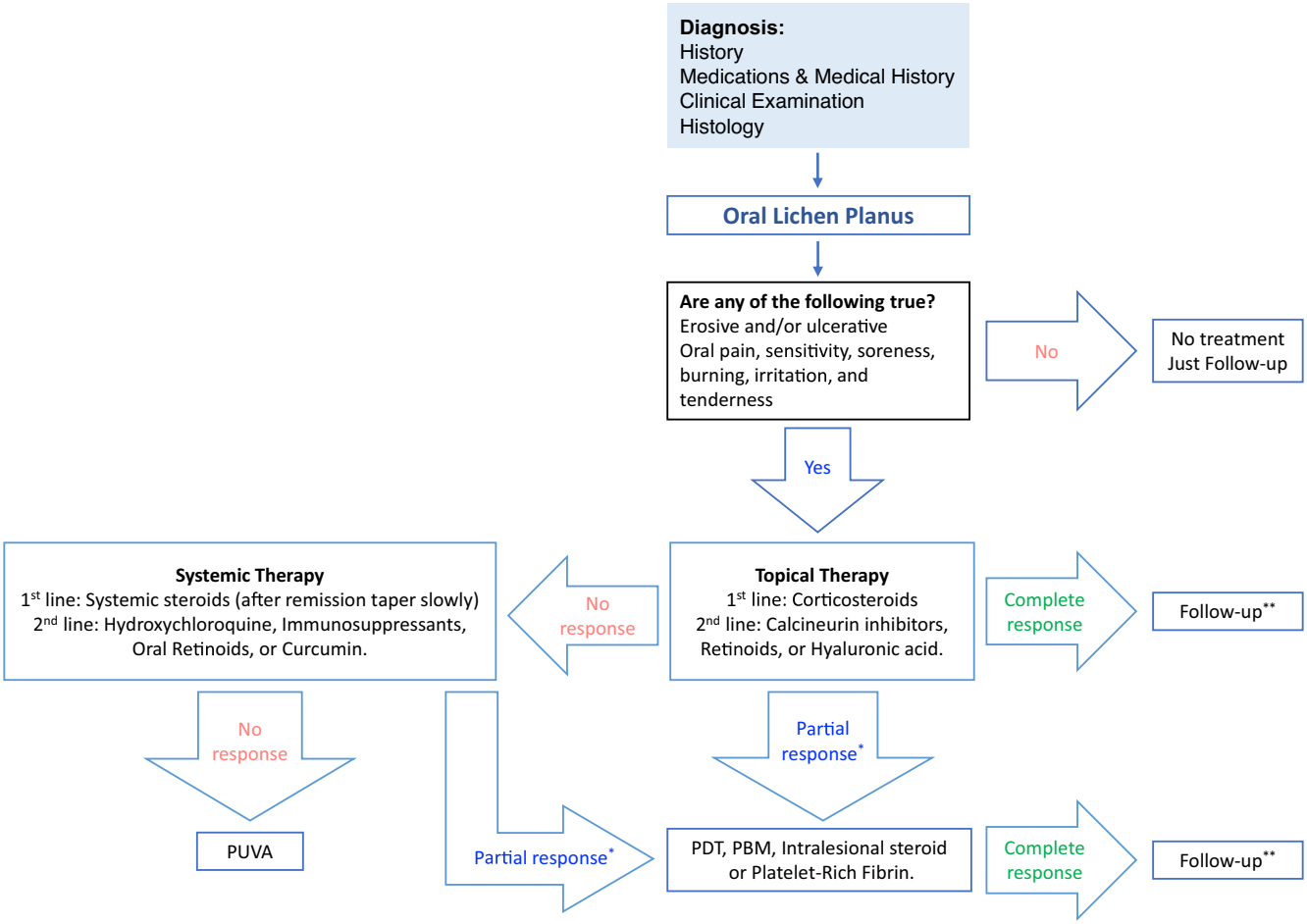

FIGURE 2 | Treating OLP recommendations. *A partial response referred to a 50%–79% decrease in active skin lesions from the baseline [132]. ** Roughly 50% of patients experience relapse, defined as the recurrence of active lesions after complete response, within 4–17 weeks [133]. [Color figure can be viewed at wileyonlinelibrary.com]

were effective in improving clinical symptoms in symptomatic OLP patients. However, due to its lower cost, clobetasol may be preferred as a first-line treatment, while tacrolimus may serve as an alternative for steroid-refractory cases [134]. The potential for systemic absorption and impact on blood glucose should be noted prior to prescribing. In the setting where systemic absorption should be avoided, budesonide may be considered or other approaches provided.

Intralesional steroids, though effective, are more invasive and costly due to procedural fees. For example, intralesional betamethasone showed a greater reduction in erosive area than 40 mg/mL triamcinolone; though pain relief was similar between groups [135].

Systemic steroids require more complex dosing schedules and carry an increased risk of side effects. Although the total cost varies depending on duration and frequency of administration, a 0.5 mg tablet of betamethasone costs around $0.58, while dapsone, another systemic option, costs about $1.92 per 100 mg tablet and has shown better efficacy compared to topical triamcinolone, tacrolimus, and retinoids [76].

PDT may offer long-term cost–benefit advantages over medication management due to fewer sessions and possible home device use. A recent RCT compared PDT and topical clobetasol for treating OLP and found both to be effective, with PDT resulting in greater lesion reduction (79.88% vs. 56.3%) and a higher complete response rate (79% vs. 62%) at 3 months. However, clobetasol remains more accessible and affordable, despite a higher relapse rate [136].

In a case–control study comparing PDT and LLLT, PDT was more effective than LLLT in modulating local inflammation (65% vs. 31% reduction in salivary IL-4); whereas LLLT showed greater pain relief (50% vs. 33.3%) [137].

9 | Conclusion

OLP is a multifactorial and increasingly common condition with significant implications for patient quality of life and a potential risk for malignant transformation. Routine monitoring and testing are usually sufficient for asymptomatic reticular OLP. OLP is not a surgically managed condition. For mild to moderate symptomatic OLP, topical corticosteroids are usually chosen as first-line treatment due to their cost–benefit ratio with continuing follow up. To treat acute exacerbations, persistent, and considerably deteriorating OLP lesions, low, brief doses of oral systemic steroids may be considered; however, long-term use should be

10970347, 0, Downloaded from https://onlinelibrary.wiley.com/doi/10.1002/hed.70012 by City Of Hope - Lee Graff Medic, Wiley Online Library on [26/08/2025]. See the Terms and Conditions (https://onlinelibrary.wiley.com/terms-and-conditions) on Wiley Online Library for rules of use; OA articles are governed by the applicable Creative Commons License

avoided. For the treatment of persistent OLP, extensive lesions, and patients who are either unresponsive to topical corticosteroids or in those at risk of oral candidiasis, topical calcineurin inhibitors and vitamin A derivatives may be used. Vitamin A derivatives may have an additional role to play in suppression of plaque-like change and dysplasia risk. Even though there is evidence that PDT sessions may be more effective and have fewer adverse effects than other treatment approaches, further study is needed. For resistant cases, combination of therapies with different mechanisms of action should be considered. Educating patients on eliminating potential carcinogens, treating erosive lesions, and maintaining a nutritious diet may also reduce cancer risk. Regular cancer screenings, biopsies when indicated due to tissue change, and a multidisciplinary medical approach that may include dental practitioners, oral medicine specialists, dermatologists, rheumatologists, and other specialists ensures comprehensive care and early intervention, essential in managing this OPMD. The development of immunomodulatory agents that target particular cytokines implicated in the LP immune response is a promising development. However, larger RCTs are required to confirm their long-term safety and effectiveness.

Author Contributions

J.B.E. and F.S. identified the need for review, developed the outline, and reviewed and edited the search strategy. E.A. conducted the literature search, created the figures and table, and drafted the original manuscript. J.B.E. and F.S. contributed to the critical revision of the manuscript. All authors read and approved the final manuscript.

Ethics Statement

The authors have nothing to report.

Consent

The authors have nothing to report.

Conflicts of Interest

The authors declare no conflicts of interest.

Data Availability Statement

Data sharing not applicable to this article as no datasets were generated or analysed during the current study.

References

1. R. Czerninski, Z. Awadieh, S. Feldman, N. Keshet, A. Zlotogorski, and Y. Ramot, "Familial Oral Lichen Planus: A New Risk Group for Oral Cancer?," *Oral Diseases* 30, no. 5 (2024): 3018–3027, https://doi.org/10.1111/odi.14805.

2. A. Elenbaas, R. Enciso, and K. Al-Eryani, "Oral Lichen Planus: A Review of Clinical Features, Etiologies, and Treatments," *Dentistry Review* 2, no. 1 (2022): 100007, https://doi.org/10.1016/j.dentre.2021.100007.

3. N. Gururaj, P. Hasinidevi, V. Janani, and T. Divynadaniel, "Diagnosis and Management of Oral Lichen Planus - Review," *Journal of Oral and Maxillofacial Pathology* 25, no. 3 (2021): 383–393, https://doi.org/10.4103/jomfp.jomfp_386_21.

4. H. Y. Nukaly, I. R. Halawani, S. M. S. Alghamdi, et al., "Oral Lichen Planus: A Narrative Review Navigating Etiologies, Clinical Manifestations, Diagnostics, and Therapeutic Approaches," *Journal of Clinical Medicine* 13, no. 17 (2024): 5280, https://doi.org/10.3390/jcm13175280.

5. E. Shavit, K. Hagen, and N. Shear, "Oral Lichen Planus: A Novel Staging and Algorithmic Approach and All That Is Essential to Know," *F1000Research* 9 (2020): F1000, https://doi.org/10.12688/f1000research.18713.1.

6. P. Ramos-García, M. Á. González-Moles, and S. Warnakulasuriya, "Oral Cancer Development in Lichen Planus and Related Conditions-3.0 Evidence Level: A Systematic Review of Systematic Reviews," *Oral Diseases* 27, no. 8 (2021): 1919–1935, https://doi.org/10.1111/odi.13812.

7. M. Á. González-Moles, S. Warnakulasuriya, I. González-Ruiz, et al., "Worldwide Prevalence of Oral Lichen Planus: A Systematic Review and Meta-Analysis," *Oral Diseases* 27, no. 4 (2021): 813–828, https://doi.org/10.1111/odi.13323.

8. C. Li, X. Tang, X. Zheng, et al., "Global Prevalence and Incidence Estimates of Oral Lichen Planus," *JAMA Dermatology* 156, no. 2 (2020): 172–181, https://doi.org/10.1001/jamadermatol.2019.3797.

9. V. Laniosz, R. R. Torgerson, A. J. Ramos-Rodriguez, et al., "Incidence of Squamous Cell Carcinoma in Oral Lichen Planus: A 25-Year Population-Based Study," *International Journal of Dermatology* 58, no. 3 (2019): 296–301, https://doi.org/10.1111/ijd.14215.

10. N. Pelet del Toro, A. Strunk, A. Garg, and G. Han, "Prevalence and Treatment Patterns of Lichen Planus," *Journal of the American Academy of Dermatology* 92, no. 4 (2025): 717–723, https://doi.org/10.1016/j.jaad.2024.09.081.

11. M. Carrozzo, "Understanding the Pathobiology of Oral Lichen Planus," *Current Oral Health Reports* 1, no. 3 (2014): 173–179, https://doi.org/10.1007/s40496-014-0022-y.

12. Z. B. Kurago, "Etiology and Pathogenesis of Oral Lichen Planus: An Overview," *Oral Surgery, Oral Medicine, Oral Pathology, Oral Radiology* 122, no. 1 (2016): 72–80, https://doi.org/10.1016/j.oooo.2016.03.011.

13. N. Lavanya, P. Jayanthi, U. K. Rao, and K. Ranganathan, "Oral Lichen Planus: An Update on Pathogenesis and Treatment," *Journal of Oral and Maxillofacial Pathology* 15, no. 2 (2011): 127–132, https://doi.org/10.4103/0973-029X.84474.

14. D. Didona, R. D. Caposiena Caro, A. M. Sequeira Santos, F. Solimani, and M. Hertl, "Therapeutic Strategies for Oral Lichen Planus: State of the Art and New Insights," *Frontier Medicine (Lausanne)* 9 (2022): 997190, https://doi.org/10.3389/fmed.2022.997190.

15. A. Khan, C. S. Farah, N. W. Savage, L. J. Walsh, D. J. Harbrow, and P. B. Sugerman, "Th1 Cytokines in Oral Lichen Planus," *Journal of Oral Pathology & Medicine* 32, no. 2 (2003): 77–83, https://doi.org/10.1034/j.1600-0714.2003.00077.x.

16. M. R. Payeras, K. Cherubini, M. A. Figueiredo, and F. G. Salum, "Oral Lichen Planus: Focus on Etiopathogenesis," *Archives of Oral Biology* 58, no. 9 (2013): 1057–1069, https://doi.org/10.1016/j.archoralbio.2013.04.004.

17. I. Alarcón, C. Alarcón, and J. Arellano, "Overview of Lichen Planus Pathogenesis and Review of Possible Future Therapies," *JAAD Reviews* 3 (2025): 146–154, https://doi.org/10.1016/j.jdrv.2025.01.011.

18. A. Santoro, A. Majorana, E. Bardellini, S. Festa, P. Sapelli, and F. Facchetti, "NF-kappaB Expression in Oral and Cutaneous Lichen Planus," *Journal of Pathology* 201, no. 3 (2003): 466–472, https://doi.org/10.1002/path.1423.

19. C. Tziotzios, J. Y. W. Lee, T. Brier, et al., "Lichen Planus and Lichenoid Dermatoses: Clinical Overview and Molecular Basis," *Journal of the American Academy of Dermatology* 79, no. 5 (2018): 789–804, https://doi.org/10.1016/j.jaad.2018.02.010.

20. C. C. Albu, M. A. Bencze, A. O. Dragomirescu, et al., "Oral Lichen Planus Genetics Update," *European Journal of Dental and Oral Health* 3, no. 4 (2022): 1–5, https://doi.org/10.24018/ejdent.2022.3.4.205.

10970347, 0, Downloaded from https://onlinelibrary.wiley.com/doi/10.1002/hed.70012 by City Of Hope - Lee Graff Medic, Wiley Online Library on [26/08/2025]. See the Terms and Conditions (https://onlinelibrary.wiley.com/terms-and-conditions) on Wiley Online Library for rules of use; OA articles are governed by the applicable Creative Commons License

21. Y. Mizukawa, C. Horie, Y. Yamazaki, and T. Shiohara, "Detection of Varicella-Zoster Virus Antigens in Lesional Skin of Zosteriform Lichen Planus but Not in That of Linear Lichen Planus," *Dermatology* 225, no. 1 (2012): 22–26, https://doi.org/10.1159/000339771.

22. R. J. Abbott, A. Pachnio, I. Pedroza-Pacheco, et al., "Asymptomatic Primary Infection With Epstein-Barr Virus: Observations on Young Adult Cases," *Journal of Virology* 91, no. 21 (2017): e00382, https://doi.org/10.1128/JVI.00382-17.

23. B. Yildirim, B. Sengüven, and C. Demir, "Prevalence of Herpes Simplex, Epstein Barr and Human Papilloma Viruses in Oral Lichen Planus," *Medicina Oral, Patología Oral y Cirugía Bucal* 16, no. 2 (2011): e170–e174, https://doi.org/10.4317/medoral.16.e170.

24. H. Raybaud, C. V. Olivieri, L. Lupi-Pegurier, et al., "Epstein-Barr Virus-Infected Plasma Cells Infiltrate Erosive Oral Lichen Planus," *Journal of Dental Research* 97, no. 13 (2018): 1494–1500, https://doi.org/10.1177/0022034518788282.

25. R. d. R. Vieira, L. L. Ferreira, É. R. Biasoli, D. G. Bernabé, C. M. Nunes, and G. I. Miyahara, "Detection of Epstein-Barr Virus in Different Sources of Materials From Patients With Oral Lichen Planus: A Case-Control Study," *Journal of Clinical Pathology* 69, no. 4 (2016): 358–363, https://doi.org/10.1136/jclinpath-2015-203325.

26. S. Kato, R. Kawai, M. Isomura, et al., "Human Papillomavirus in Oral Lichen Planus of Japanese Patients," *Journal of Hard Tissue Biology* 24, no. 2 (2015): 181–188, https://doi.org/10.2485/jhtb.24.181.

27. J. Ma, J. Zhang, Y. Zhang, T. Lv, and J. Liu, "The Magnitude of the Association Between Human Papillomavirus and Oral Lichen Planus: A Meta-Analysis," *PLoS One* 11, no. 8 (2016): e0161339, https://doi.org/10.1371/journal.pone.0161339.

28. Y. Nahidi, N. Tayyebi Meibodi, K. Ghazvini, H. Esmaily, and M. Esmaeelzadeh, "Association of Classic Lichen Planus With Human Herpesvirus-7 Infection," *International Journal of Dermatology* 56, no. 1 (2017): 49–53, https://doi.org/10.1111/ijd.13416.

29. H. J. C. de Vries, M. B. M. Teunissen, F. Zorgdrager, D. Picavet, and M. Cornelissen, "Lichen Planus Remission Is Associated With a Decrease of Human Herpes Virus Type 7 Protein Expression in Plasmacytoid Dendritic Cells," *Archives of Dermatological Research* 299, no. 4 (2007): 213–219, https://doi.org/10.1007/s00403-007-0750-0.

30. S. H. Ma, Y. H. Tai, Y. X. Dai, Y. T. Chang, T. J. Chen, and M. H. Chen, "Association Between Hepatitis C Virus Infection and Subsequent Chronic Inflammatory Skin Disease," *Journal of Dermatology* 48, no. 12 (2021): 1884–1891, https://doi.org/10.1111/1346-8138.16129.

31. N. A. Alaizari, S. A. Al-Maweri, H. M. Al-Shamiri, B. Tarakji, and B. Shugaa-Addin, "Hepatitis C Virus Infections in Oral Lichen Planus: A Systematic Review and Meta-Analysis," *Australian Dental Journal* 61, no. 3 (2016): 282–287, https://doi.org/10.1111/adj.12382.

32. S. Petti, M. Rabiei, M. De Luca, and C. Scully, "The Magnitude of the Association Between Hepatitis C Virus Infection and Oral Lichen Planus: Meta-Analysis and Case Control Study," *Odontology* 99, no. 2 (2011): 168–178, https://doi.org/10.1007/s10266-011-0008-3.

33. S. R. Georgescu, M. Tampa, M. I. Mitran, et al., "Potential Pathogenic Mechanisms Involved in the Association Between Lichen Planus and Hepatitis C Virus Infection," *Experimental and Therapeutic Medicine* 17, no. 2 (2019): 1045–1051, https://doi.org/10.3892/etm.2018.6987.

34. H. Y. Zheng, M. Zhang, C. X. Yang, et al., "Elevated Exhaustion Levels and Reduced Functional Diversity of T Cells in Peripheral Blood May Predict Severe Progression in COVID-19 Patients," *Cellular & Molecular Immunology* 17, no. 5 (2020): 541–543, https://doi.org/10.1038/s41423-020-0401-3.

35. C. Qin, L. Zhou, Z. Hu, et al., "Dysregulation of Immune Response in Patients With Coronavirus 2019 (COVID-19) in Wuhan, China," *Clinical Infectious Diseases* 71, no. 15 (2020): 762–768, https://doi.org/10.1093/cid/ciaa248.

36. L. Alabdulaaly, H. Sroussi, and J. B. Epstein, "New Onset and Exacerbation of Oral Lichenoid Mucositis Following SARS-CoV-2 Infection or Vaccination," *Oral Diseases* 28, no. S2 (2022): 2563–2567, https://doi.org/10.1111/odi.14257.

37. V. Fidan, H. Koyuncu, and O. Akin, "Oral Lesions in Covid 19 Positive Patients," *American Journal of Otolaryngology* 42, no. 3 (2021): 102905, https://doi.org/10.1016/j.amjoto.2021.102905.

38. M. Hertel, A. M. Schmidt-Westhausen, S. Wendy, et al., "Onset of Oral Lichenoid Lesions and Oral Lichen Planus Following COVID-19 Vaccination: A Retrospective Analysis of About 300,000 Vaccinated Patients," *Vaccines (Basel)* 10, no. 3 (2022): 480, https://doi.org/10.3390/vaccines10030480.

39. G. P. Bombeccari, M. Tettamanti, F. Pallotti, F. Spadari, and A. B. Giannì, "Exacerbations of Oral Lichen Planus and Elevated Levels of Aminotransferases," *International Journal of Dermatology* 56, no. 8 (2017): 842–849, https://doi.org/10.1111/ijd.13626.

40. D. Lin, L. Yang, L. Wen, H. Lu, Q. Chen, and Z. Wang, "Crosstalk Between the Oral Microbiota, Mucosal Immunity, and the Epithelial Barrier Regulates Oral Mucosal Disease Pathogenesis," *Mucosal Immunology* 14, no. 6 (2021): 1247–1258, https://doi.org/10.1038/s41385-021-00413-7.

41. W. Jung and S. Jang, "Oral Microbiome Research on Oral Lichen Planus: Current Findings and Perspectives," *Biology (Basel)* 11, no. 5 (2022): 723, https://doi.org/10.3390/biology11050723.

42. K. Belhareth, M. Korbi, H. Belhadjali, et al., "Pediatric Lichen Planus Pigmentosus Possibly Triggered by Mercury Dental Amalgams," *Pediatric Dermatology* 37, no. 2 (2020): 375–376, https://doi.org/10.1111/pde.14078.

43. T. F. Rasul, J. Anderson, D. R. Bergholz, A. Faiz, and R. R. Prasad, "Gold Dental Implant-Induced Oral Lichen Planus," *Cureus* 14, no. 2 (2022): e21852, https://doi.org/10.7759/cureus.21852.

44. H. Yaribeygi, Y. Panahi, H. Sahraei, T. P. Johnston, and A. Sahebkar, "The Impact of Stress on Body Function: A Review," *EXCLI Journal* 16 (2017): 1057–1072, https://doi.org/10.17179/excli2017-480.

45. N. L. Rhodus, B. Cheng, and F. Ondrey, "Th1/Th2 Cytokine Ratio in Tissue Transudates From Patients With Oral Lichen Planus," *Mediators of Inflammation* 2007 (2007): 19854, https://doi.org/10.1155/2007/19854.

46. R. Belkacem Chebil, Y. Oueslati, M. Marzouk, F. Ben Fredj, L. Oualha, and N. Douki, "Oral Lichen Planus and Lichenoid Lesions in Sjogren's Syndrome Patients: A Prospective Study," *International Journal of Dentistry* 2019 (2019): 1603657, https://doi.org/10.1155/2019/1603657.

47. T. De Porras-Carrique, P. Ramos-García, M. Aguilar-Diosdado, S. Warnakulasuriya, and M. Á. González-Moles, "Autoimmune Disorders in Oral Lichen Planus: A Systematic Review and Meta-Analysis," *Oral Diseases* 29, no. 4 (2023): 1382–1394, https://doi.org/10.1111/odi.14127.

48. M. M. S. Nico, M. A. C. Vilela, E. A. Rivitti, and S. V. Lourenço, "Oral Lesions in Lupus Erythematosus: Correlation With Cutaneous Lesions," *European Journal of Dermatology* 18, no. 4 (2008): 376–381, https://doi.org/10.1684/ejd.2008.0388.

49. T. Zhou, D. Li, Q. Chen, H. Hua, and C. Li, "Correlation Between Oral Lichen Planus and Thyroid Disease in China: A Case-Control Study," *Frontiers in Endocrinology* 9 (2018): 330, https://doi.org/10.3389/fendo.2018.00330.

50. M. J. Garcia-Pola, S. Llorente-Pendás, J. M. Seoane-Romero, M. J. Berasaluce, and J. M. García-Martín, "Thyroid Disease and Oral Lichen Planus as Comorbidity: A Prospective Case-Control Study," *Dermatology* 232, no. 2 (2016): 214–219, https://doi.org/10.1159/000442438.

51. K. M. Kumar, N. Nachiammai, and G. S. Madhushankari, "Association of Oral Manifestations in Ulcerative Colitis: A Pilot Study,"

10970347, 0, Downloaded from https://onlinelibrary.wiley.com/doi/10.1002/hed.70012 by City Of Hope - Lee Graff Medic, Wiley Online Library on [26/08/2025]. See the Terms and Conditions (https://onlinelibrary.wiley.com/terms-and-conditions) on Wiley Online Library for rules of use; OA articles are governed by the applicable Creative Commons License

Journal of Oral and Maxillofacial Pathology: JOMFP 22, no. 2 (2018): 199–203, https://doi.org/10.4103/jomfp.JOMFP_223_16.

52. R. Darlenski, V. Mihaylova, and T. Handjieva-Darlenska, "The Link Between Obesity and the Skin," *Frontiers in Nutrition* 9 (2022): 855573, https://doi.org/10.3389/fnut.2022.855573.

53. A. Dave, J. Shariff, and E. Philipone, "Association Between Oral Lichen Planus and Systemic Conditions and Medications: Case-Control Study," *Oral Diseases* 27, no. 3 (2021): 515–524, https://doi.org/10.1111/odi.13572.

54. H. R. Mozaffari, R. Sharifi, and M. Sadeghi, "Prevalence of Oral Lichen Planus in Diabetes Mellitus: A Meta-Analysis Study," *Acta Informatica Medica* 24, no. 6 (2016): 390–393, https://doi.org/10.5455/aim.2016.24.390-393.

55. M. Daye, S. A. Temiz, and B. Isık, "The Relationship Between Lichen Planus and Metabolic Syndrome," *Journal of Cosmetic Dermatology* 20, no. 8 (2021): 2635–2639, https://doi.org/10.1111/jocd.13905.

56. B. Dudhia, S. Dudhia, P. Patel, and Y. Jani, "Oral Lichen Planus to Oral Lichenoid Lesions: Evolution or Revolution," *Journal of Oral and Maxillofacial Pathology* 19, no. 3 (2015): 364–370, https://doi.org/10.4103/0973-029X.174632.

57. Z. Rotim, Z. Bolanca, A. A. Rogulj, M. Andabak, V. V. Boras, and D. V. Vrdoljak, "Oral Lichen Planus and Oral Lichenoid Reaction–An Update," *Acta Clinica Croatica* 54, no. 4 (2015): 516–520, http://www.ncbi.nlm.nih.gov/pubmed/27017728.

58. N. Ghazi, N. Saghravanian, M. Mirhashemi, and H. Shahabi, "Histologic and Histomorphometric Comparative Study of Oral Lichen Planus Versus Oral Lichenoid Reaction," *Indian Journal of Otolaryngology and Head & Neck Surgery* 76, no. 2 (2024): 1785–1790, https://doi.org/10.1007/s12070-023-04411-y.

59. D. I. Rotaru, "Diagnostic Criteria of Oral Lichen Planus: A Narrative Review," *Acta Clinica Croatica* 59, no. 3 (2020): 513–522, https://doi.org/10.20471/acc.2020.59.03.16.

60. N. G. Barbosa, É. J. D. Silveira, A. Lima EN de, P. T. Oliveira, and A. M. C. de Medeiros, "Factors Associated With Clinical Characteristics and Symptoms in a Case Series of Oral Lichen Planus," *International Journal of Dermatology* 54, no. 1 (2015): e1–e6, https://doi.org/10.1111/ijd.12485.

61. M. Boorghani, N. Gholizadeh, A. Taghavi Zenouz, M. Vatankhah, and M. Mehdipour, "Oral Lichen Planus: Clinical Features, Etiology, Treatment and Management; a Review of Literature," *Journal of Dental Research, Dental Clinics, Dental Prospects* 4, no. 1 (2010): 3–9, https://doi.org/10.5681/joddd.2010.002.

62. D. Eisen, M. Carrozzo, J. V. Bagan Sebastian, and K. Thongprasom, "Number V Oral Lichen Planus: Clinical Features and Management," *Oral Diseases* 11, no. 6 (2005): 338–349, https://doi.org/10.1111/j.1601-0825.2005.01142.x.

63. G. Mergoni, S. Ergun, P. Vescovi, Ö. Mete, H. Tanyeri, and M. Meleti, "Oral Postinflammatory Pigmentation: An Analysis of 7 Cases," *Medicina Oral, Patología Oral y Cirugía Bucal* 16, no. 1 (2011): e11–e14, https://doi.org/10.4317/medoral.16.e11.

64. M. Á. González-Moles and P. Ramos-García, "An Evidence-Based Update on the Potential for Malignancy of Oral Lichen Planus and Related Conditions: A Systematic Review and Meta-Analysis," *Cancers* 16, no. 3 (2024): 608, https://doi.org/10.3390/cancers16030608.

65. H. Zhang, B. Xu, J. Liu, B. Guo, H. Sun, and Q. Yang, "SDHB Reduction Promotes Oral Lichen Planus by Impairing Mitochondrial Respiratory Function," *Annals of Translational Medicine* 10, no. 24 (2022): 1367, https://doi.org/10.21037/atm-22-5999.

66. P. Chaiyarit, N. Ma, Y. Hiraku, et al., "Nitrative and Oxidative DNA Damage in Oral Lichen Planus in Relation to Human Oral Carcinogenesis," *Cancer Science* 96, no. 9 (2005): 553–559, https://doi.org/10.1111/j.1349-7006.2005.00096.x.

67. S. Gandolfo, L. Richiardi, M. Carrozzo, et al., "Risk of Oral Squamous Cell Carcinoma in 402 Patients With Oral Lichen Planus: A Follow-Up Study in an Italian Population," *Oral Oncology* 40, no. 1 (2004): 77–83, https://doi.org/10.1016/s1368-8375(03)00139-8.

68. F. Tsushima, J. Sakurai, A. Uesugi, et al., "Malignant Transformation of Oral Lichen Planus: A Retrospective Study of 565 Japanese Patients," *BMC Oral Health* 21, no. 1 (2021): 298, https://doi.org/10.1186/s12903-021-01652-7.

69. M. A. Gonzalez-Moles, C. Scully, and J. A. Gil-Montoya, "Oral Lichen Planus: Controversies Surrounding Malignant Transformation," *Oral Diseases* 14, no. 3 (2008): 229–243, https://doi.org/10.1111/j.1601-0825.2008.01441.x.

70. E. H. van der Meij, K. P. Schepman, and I. van der Waal, "The Possible Premalignant Character of Oral Lichen Planus and Oral Lichenoid Lesions: A Prospective Study," *Oral Surgery, Oral Medicine, Oral Pathology, Oral Radiology, and Endodontics* 96, no. 2 (2003): 164–171, https://doi.org/10.1016/s1079-2104(03)00305-6.

71. E. Akbari, J. B. Epstein, and F. Samim, "Unveiling the Hidden Links: Periodontal Disease, Fusobacterium Nucleatum, and Cancers," *Current Oncology Reports* 26 (2024): 1388–1397, https://doi.org/10.1007/s11912-024-01591-w.

72. M. Mignogna, "Clinical Guidelines in Early Detection of Oral Squamous Cell Carcinoma Arising in Oral Lichen Planus: A 5-Year Experience," *Oral Oncology* 37, no. 3 (2001): 262–267, https://doi.org/10.1016/S1368-8375(00)00096-8.

73. D. Lauritano, M. Arrica, A. Lucchese, et al., "Oral Lichen Planus Clinical Characteristics in Italian Patients: A Retrospective Analysis," *Head & Face Medicine* 12, no. 1 (2016): 18, https://doi.org/10.1186/s13005-016-0115-z.

74. N. Ghazi and M. Khorasanchi, "Markers Associated With Malignant Transformation of Oral Lichen Planus: A Review Article," *Archives of Oral Biology* 127 (2021): 105158, https://doi.org/10.1016/j.archoralbio.2021.105158.

75. V. S. Ayyar and W. J. Jusko, "Transitioning From Basic Toward Systems Pharmacodynamic Models: Lessons From Corticosteroids," *Pharmacological Reviews* 72, no. 2 (2020): 414–438, https://doi.org/10.1124/pr.119.018101.

76. S. Sandhu, B. A. Klein, M. Al-Hadlaq, et al., "Oral Lichen Planus: Comparative Efficacy and Treatment Costs-a Systematic Review," *BMC Oral Health* 22, no. 1 (2022): 161, https://doi.org/10.1186/s12903-022-02168-4.

77. A. Andabak-Rogulj, E. Vindiš, L. H. Aleksijević, et al., "Different Treatment Modalities of Oral Lichen Planus-A Narrative Review," *Dent Journal (Basel)* 11, no. 1 (2023): 26, https://doi.org/10.3390/dj11010026.

78. M. Bindakhil, S. Akintoye, P. Corby, et al., "Influence of Topical Corticosteroids on Malignant Transformation of Oral Lichen Planus," *Journal of Oral Pathology & Medicine* 51, no. 2 (2022): 188–193, https://doi.org/10.1111/jop.13257.

79. R. A. Utsman, J. B. Epstein, and S. Elad, "Budesonide for Local Therapy of Complex Oral Mucosal Immune-Mediated Inflammatory Diseases: Case Reports," *Oral Surgery, Oral Medicine, Oral Pathology, Oral Radiology, and Endodontology* 106, no. 1 (2008): e11–e17, https://doi.org/10.1016/j.tripleo.2008.02.029.

80. J. K. Ku, S. Y. Park, K. G. Hwang, and P. Y. Yun, "The Effect of Mouthrinse With 0.05% Dexamethasone Solution on the Oral Bacterial Community of Oral Lichen Planus Patients: Prospective Pilot Study," *Applied Sciences* 11, no. 14 (2021): 6286, https://doi.org/10.3390/app11146286.

81. M. Carbone, E. Goss, M. Carrozzo, et al., "Systemic and Topical Corticosteroid Treatment of Oral Lichen Planus: A Comparative Study With Long-Term Follow-Up," *Journal of Oral Pathology & Medicine* 32, no. 6 (2003): 323–329, https://doi.org/10.1034/j.1600-0714.2003.00173.x.

10970347, 0, Downloaded from https://onlinelibrary.wiley.com/doi/10.1002/hed.70012 by City Of Hope - Lee Graff Medic, Wiley Online Library on [26/08/2025]. See the Terms and Conditions (https://onlinelibrary.wiley.com/terms-and-conditions) on Wiley Online Library for rules of use; OA articles are governed by the applicable Creative Commons License

82. S. T. Sharma and L. K. Nieman, "Cushing's Syndrome: All Variants, Detection, and Treatment," *Endocrinology and Metabolism Clinics of North America* 40, no. 2 (2011): 379–391, https://doi.org/10.1016/j.ecl.2011.01.006.

83. P. B. Sugerman and N. W. Savage, "Oral Lichen Planus: Causes, Diagnosis and Management," *Australian Dental Journal* 47, no. 4 (2002): 290–297, https://doi.org/10.1111/j.1834-7819.2002.tb00540.x.

84. J. S. Wee, P. J. Shirlaw, S. J. Challacombe, and J. F. Setterfield, "Efficacy of Mycophenolate Mofetil in Severe Mucocutaneous Lichen Planus: A Retrospective Review of 10 Patients," *British Journal of Dermatology* 167, no. 1 (2012): 36–43, https://doi.org/10.1111/j.1365-2133.2012.10882.x.

85. M. Schifter, S. Yeoh, H. Coleman, and A. Georgiou, "Oral Mucosal Diseases: The Inflammatory Dermatoses," *Australian Dental Journal* 55, no. s1 (2010): 23–38, https://doi.org/10.1111/j.1834-7819.2010.01196.x.

86. T. Wu, Y. Bai, Y. Jing, and F. Chen, "What Can We Learn From Treatments of Oral Lichen Planus?," *Frontiers in Cellular and Infection Microbiology* 14 (2024): 14, https://doi.org/10.3389/fcimb.2024.1279220.

87. M. Radwan-Oczko, "Topical Application of Drugs Used in Treatment of Oral Lichen Planus Lesions," *Advances in Clinical and Experimental Medicine* 22, no. 6 (2013): 893–898, http://www.ncbi.nlm.nih.gov/pubmed/24431320.

88. I. Al-Hashimi, M. Schifter, P. B. Lockhart, et al., "Oral Lichen Planus and Oral Lichenoid Lesions: Diagnostic and Therapeutic Considerations," *Oral Surgery, Oral Medicine, Oral Pathology, Oral Radiology, and Endodontics* 103 (2007): S25.e1–S25.e12, https://doi.org/10.1016/j.tripleo.2006.11.001.

89. J. B. Epstein and E. L. Truelove, "Topical Cyclosporine in a Bioadhesive for Treatment of Oral Lichenoid Mucosal Reactions: An Open Label Clinical Trial," *Oral Surgery, Oral Medicine, Oral Pathology, Oral Radiology, and Endodontology* 82, no. 5 (1996): 532–536, https://doi.org/10.1016/s1079-2104(96)80198-3.

90. P. Germain, P. Chambon, G. Eichele, et al., "International Union of Pharmacology. LXIII. Retinoid X Receptors," *Pharmacological Reviews* 58, no. 4 (2006): 760–772, https://doi.org/10.1124/pr.58.4.7.

91. M. Petruzzi, A. Lucchese, C. Lajolo, G. Campus, D. Lauritano, and R. Serpico, "Topical Retinoids in Oral Lichen Planus Treatment: An Overview," *Dermatology* 226, no. 1 (2013): 61–67, https://doi.org/10.1159/000346750.

92. B. Lindelöf, B. Sigurgeirsson, E. Tegner, et al., "PUVA and Cancer: A Large-Scale Epidemiological Study," *Lancet* 338, no. 8759 (1991): 91–93, https://doi.org/10.1016/0140-6736(91)90083-2.

93. R. Kassem, N. Yarom, A. Scope, M. Babaev, H. Trau, and F. Pavlotzky, "Treatment of Erosive Oral Lichen Planus With Local Ultraviolet B Phototherapy," *Journal of the American Academy of Dermatology* 66, no. 5 (2012): 761–766, https://doi.org/10.1016/j.jaad.2011.04.017.

94. Z. Ślebioda and B. Dorocka-Bobkowska, "Low-Level Laser Therapy in the Treatment of Recurrent Aphthous Stomatitis and Oral Lichen Planus: A Literature Review," *Postepy Dermatologii I Alergologii* 37, no. 4 (2020): 475–481, https://doi.org/10.5114/ada.2020.98258.

95. M. M. Khater and F. M. Khattab, "Efficacy of 1064 Q Switched Nd:YAG Laser in the Treatment of Oral Lichen Planus," *Journal of Dermatological Treatment* 31, no. 6 (2020): 655–659, https://doi.org/10.1080/09546634.2019.1638881.

96. A. S. Ertugrul, U. Arslan, R. Dursun, and S. S. Hakki, "Periodontopathogen Profile of Healthy and Oral Lichen Planus Patients With Gingivitis or Periodontitis," *International Journal of Oral Science* 5, no. 2 (2013): 92–97, https://doi.org/10.1038/ijos.2013.30.

97. A. Del Vecchio, G. Palaia, B. Grassotti, et al., "Effects of Laser Photobiomodulation in the Management of Oral Lichen Planus: A Literature Review," *La Clinica Terapeutica* 172, no. 5 (2021): 467–483, https://doi.org/10.7417/CT.2021.2360.

98. Z. Akram, T. Abduljabbar, F. Vohra, and F. Javed, "Efficacy of Low-Level Laser Therapy Compared to Steroid Therapy in the Treatment of Oral Lichen Planus: A Systematic Review," *Journal of Oral Pathology & Medicine* 47, no. 1 (2018): 11–17, https://doi.org/10.1111/jop.12619.

99. Y. He, J. Deng, Y. Zhao, et al., "Efficacy Evaluation of Photodynamic Therapy for Oral Lichen Planus: A Systematic Review and Meta-Analysis," *BMC Oral Health* 20, no. 1 (2020): 302, https://doi.org/10.1186/s12903-020-01260-x.

100. S. Bakhtiari, S. Azari-Marhabi, S. M. Mojahedi, M. Namdari, Z. E. Rankohi, and S. Jafari, "Comparing Clinical Effects of Photodynamic Therapy as a Novel Method With Topical Corticosteroid for Treatment of Oral Lichen Planus," *Photodiagnosis and Photodynamic Therapy* 20 (2017): 159–164, https://doi.org/10.1016/j.pdpdt.2017.06.002.

101. F. Lavaee and M. Shadmanpour, "Comparison of the Effect of Photodynamic Therapy and Topical Corticosteroid on Oral Lichen Planus Lesions," *Oral Diseases* 25, no. 8 (2019): 1954–1963, https://doi.org/10.1111/odi.13188.

102. W. Saleh and O. Khashaba, "Clinical Responses of Patients With Systemic Diseases to the Photodynamic Therapy of Oral Lichen Planus," *Photodiagnosis and Photodynamic Therapy* 39 (2022): 102972, https://doi.org/10.1016/j.pdpdt.2022.102972.

103. R. Cosgarea, R. Pollmann, J. Sharif, et al., "Photodynamic Therapy in Oral Lichen Planus: A Prospective Case-Controlled Pilot Study," *Scientific Reports* 10, no. 1 (2020): 1667, https://doi.org/10.1038/s41598-020-58548-9.

104. D. Eisen, "Hydroxychloroquine Sulfate (Plaquenil) Improves Oral Lichen Planus: An Open Trial," *Journal of the American Academy of Dermatology* 28, no. 4 (1993): 609–612, https://doi.org/10.1016/0190-9622(93)70082-5.

105. E. R. Bendas, H. Abdullah, M. H. M. El-Komy, and M. A. A. Kassem, "Hydroxychloroquine Niosomes: A New Trend in Topical Management of Oral Lichen Planus," *International Journal of Pharmaceutics* 458, no. 2 (2013): 287–295, https://doi.org/10.1016/j.ijpharm.2013.10.042.

106. N. Rivas-Tolosa, C. Requena, B. Llombart, et al., "Antimalarial Drugs for the Treatment of Oral Erosive Lichen Planus," *Dermatology* 232, no. 1 (2016): 86–90, https://doi.org/10.1159/000439588.

107. A. Yeshurun, R. Bergman, N. Bathish, and Z. Khamaysi, "Hydroxychloroquine Sulphate Therapy of Erosive Oral Lichen Planus," *Australasian Journal of Dermatology* 60, no. 2 (2019): e109–e112, https://doi.org/10.1111/ajd.12948.

108. Y. Zhu, J. Li, Y. Bai, et al., "Hydroxychloroquine Decreases the Upregulated Frequencies of Tregs in Patients With Oral Lichen Planus," *Clinical Oral Investigations* 18, no. 8 (2014): 1903–1911, https://doi.org/10.1007/s00784-013-1176-z.

109. P. Chirravur, H. Sroussi, N. Treister, et al., "Hydroxychloroquine for the Management of Recalcitrant Oral Lichen Planus," *Oral Surgery, Oral Medicine, Oral Pathology, Oral Radiology* 137, no. 4 (2024): 355–361, https://doi.org/10.1016/j.oooo.2023.12.007.

110. Y. Xie, H. Xu, C. Li, et al., "Hydroxychloroquine Is Effective in Oral Lichen Planus: A Multicenter, Randomized, Controlled Trial," *Oral Diseases* 30, no. 5 (2024): 3126–3135, https://doi.org/10.1111/odi.14746.

111. C. M. Magro and A. N. Crowson, "Lichenoid and Granulomatous Dermatitis," *International Journal of Dermatology* 39, no. 2 (2000): 126–133, https://doi.org/10.1046/j.1365-4362.2000.00868.x.

112. F. Keshavarzi, "Fungistatic Effect of Hydroxychloroquine, Lessons From a Case," *Medical Mycology Case Reports* 13 (2016): 17–18, https://doi.org/10.1016/j.mmcr.2016.09.003.

113. Y. Zhang, C. Mao, J. Zhu, et al., "Effect of Platelet Concentrates for Pain and Symptom Management in Oral Lichen Planus: An

10970347, 0, Downloaded from https://onlinelibrary.wiley.com/doi/10.1002/hed.70012 by City Of Hope - Lee Graff Medic, Wiley Online Library on [26/08/2025]. See the Terms and Conditions (https://onlinelibrary.wiley.com/terms-and-conditions) on Wiley Online Library for rules of use; OA articles are governed by the applicable Creative Commons License

Evidence-Based Systematic Review," *BMC Oral Health* 23, no. 1 (2023): 594, https://doi.org/10.1186/s12903-023-03296-1.

114. E. Mijiritsky, H. D. Assaf, O. Peleg, M. Shacham, L. Cerroni, and L. Mangani, "Use of PRP, PRF and CGF in Periodontal Regeneration and Facial Rejuvenation-A Narrative Review," *Biology* 10, no. 4 (2021): 317, https://doi.org/10.3390/biology10040317.

115. Z. Y. Ding, Y. Tan, Q. Peng, J. Zuo, and N. Li, "Novel Applications of Platelet Concentrates in Tissue Regeneration (Review)," *Experimental and Therapeutic Medicine* 21, no. 3 (2021): 226, https://doi.org/10.3892/etm.2021.9657.

116. S. Sriram, S. Hasan, A. Alqarni, et al., "Efficacy of Platelet-Rich Plasma Therapy in Oral Lichen Planus: A Systematic Review," *Medicina (Kaunas, Lithuania)* 59, no. 4 (2023): 746, https://doi.org/10.3390/medicina59040746.

117. S. Gunasekaran, S. Sakthivel, M. Sb, G. Babu, and V. Vijayan, "Clinical Application of Platelet-Rich Fibrin in Pediatric Dentistry," *Journal of Health and Allied Sciences NU* 12, no. 2 (2022): 186–190, https://doi.org/10.1055/s-0041-1736269.

118. N. Gupta, A. Bhargava, S. Saigal, S. Sharma, M. Patel, and O. Prakash, "Effectiveness of Injectable Platelet-Rich Fibrin in the Treatment of Oral Lichen Planus: A Systematic Review and Meta-Analysis," *Cureus* 16, no. 1 (2024): e51626, https://doi.org/10.7759/cureus.51626.

119. N. Chainani-Wu, S. Silverman, A. Reingold, et al., "A Randomized, Placebo-Controlled, Double-Blind Clinical Trial of Curcuminoids in Oral Lichen Planus," *Phytomedicine* 14, no. 7–8 (2007): 437–446, https://doi.org/10.1016/j.phymed.2007.05.003.

120. C. M. White, K. Chamberlin, and E. Eisenberg, "Curcumin, a Turmeric Extract, for Oral Lichen Planus: A Systematic Review," *Oral Diseases* 25, no. 3 (2019): 720–725, https://doi.org/10.1111/odi.13034.

121. N. Chainani-Wu, E. Madden, F. Lozada-Nur, and S. Silverman, "High-Dose Curcuminoids Are Efficacious in the Reduction in Symptoms and Signs of Oral Lichen Planus," *Journal of the American Academy of Dermatology* 66, no. 5 (2012): 752–760, https://doi.org/10.1016/j.jaad.2011.04.022.

122. S. J. Kia, S. Shirazian, A. Mansourian, L. Khodadadi Fard, and S. Ashnagar, "Comparative Efficacy of Topical Curcumin and Triamcinolone for Oral Lichen Planus: A Randomized, Controlled Clinical Trial," *Journal of Dentistry (Tehran)* 12, no. 11 (2015): 789–796, http://www.ncbi.nlm.nih.gov/pubmed/27507989.

123. M. Amirchaghmaghi, A. Pakfetrat, Z. Delavarian, H. Ghalavani, and A. Ghazi, "Evaluation of the Efficacy of Curcumin in the Treatment of Oral Lichen Planus: A Randomized Controlled Trial," *Journal of Clinical and Diagnostic Research* 10, no. 5 (2016): ZC134–ZC1347, https://doi.org/10.7860/JCDR/2016/16338.7870.

124. L. Zeng, T. Yang, K. Yang, et al., "Curcumin and *Curcuma longa* Extract in the Treatment of 10 Types of Autoimmune Diseases: A Systematic Review and Meta-Analysis of 31 Randomized Controlled Trials," *Frontiers in Immunology* 13 (2022): 896476, https://doi.org/10.3389/fimmu.2022.896476.

125. R. R. Shetty, K. N. Burde, and K. S. Guttal, "The Efficacy of Topical Hyaluronic Acid 0.2% in the Management of Symptomatic Oral Lichen Planus," *Journal of Clinical and Diagnostic Research* 10, no. 1 (2016): ZC46–ZC50, https://doi.org/10.7860/JCDR/2016/15934.7101.

126. A. S. Hashem, R. Issrani, T. E. E. Elsayed, and N. Prabhu, "Topical Hyaluronic Acid in the Management of Oral Lichen Planus: A Comparative Study," *Journal of Investigative and Clinical Dentistry* 10, no. 2 (2019): e12385, https://doi.org/10.1111/jicd.12385.

127. S. Saeed, P. Choudhury, S. A. Ahmad, et al., "Vitamin D in the Treatment of Oral Lichen Planus: A Systematic Review," *Biomedicine* 10, no. 11 (2022): 2964, https://doi.org/10.3390/biomedicines10112964.

128. J. Nazeer, S. Singh, C. Jayam, R. Singh, M. A. Iqubal, and R. Singh, "Assessment of the Role of Vitamin D in the Treatment of Oral Lichen Planus," *Journal of Contemporary Dental Practice* 21, no. 4 (2020): 390–395, http://www.ncbi.nlm.nih.gov/pubmed/32584274.

129. J. L. Xue, M. W. Fan, S. Z. Wang, X. M. Chen, Y. Li, and L. Wang, "A Clinical Study of 674 Patients With Oral Lichen Planus in China," *Journal of Oral Pathology & Medicine* 34, no. 8 (2005): 467–472, https://doi.org/10.1111/j.1600-0714.2005.00341.x.

130. Y. Wu, H. Xu, Y. Wang, et al., "An Improved Scoring System for Monitoring Oral Lichen Planus: A Preliminary Clinical Study," *Oral Diseases* 29, no. 8 (2023): 3337–3345, https://doi.org/10.1111/odi.14273.

131. N. R. Amin, N. Yussif, and E. Ahmed, "The Effect of Smoking on Clinical Presentation and Expression of TLR-2 and CD34 in Oral Lichen Planus Patients: Clinical and Immunohistochemical Study," *BMC Oral Health* 20, no. 1 (2020): 129, https://doi.org/10.1186/s12903-020-01118-2.

132. L. Atzmony, O. Reiter, E. Hodak, M. Gdalevich, and D. Mimouni, "Treatments for Cutaneous Lichen Planus: A Systematic Review and Meta-Analysis," *American Journal of Clinical Dermatology* 17, no. 1 (2016): 11–22, https://doi.org/10.1007/s40257-015-0160-6.

133. P. Wongpakorn, S. Chantarangsu, and C. Prapinjumrune, "Factors Involved in the Remission of Oral Lichen Planus Treated With Topical Corticosteroids," *BDJ Open* 10, no. 1 (2024): 34, https://doi.org/10.1038/s41405-024-00217-4.

134. F. M. M. Schroeder, E. S. Pedraça, V. M. Palma, et al., "Topical Tacrolimus Orabase Versus Topical Clobetasol Propionate Orabase in the Treatment of Symptomatic Oral Lichen Planus: A Pilot Randomized Study," *Clinical Oral Investigations* 28, no. 10 (2024): 559, https://doi.org/10.1007/s00784-024-05943-5.

135. G. Serafini, A. De Biase, L. Lamazza, G. Mazzucchi, and M. Lollobrigida, "Efficacy of Topical Treatments for the Management of Symptomatic Oral Lichen Planus: A Systematic Review," *International Journal of Environmental Research and Public Health* 20, no. 2 (2023): 1202, https://doi.org/10.3390/ijerph20021202.

136. J. Zborowski, D. Kida, B. Karolewicz, K. Jurczyszyn, and T. Konopka, "A Comparison of Photodynamic Therapy and Topical Clobetasol in Treatment of Oral Lichen Planus: A Split-Mouth Randomized Controlled Study," *Journal of Clinical Medicine* 14, no. 3 (2025): 681, https://doi.org/10.3390/jcm14030681.

137. M. A. Sabry, M. E. Gheith, A. A. Hussine, A. M. E. El Sayed, S. H. Elkady, and D. M. Abd El Aziz, "Evaluation of the Effect of Low-Level Laser Therapy Versus Photodynamic Therapy on the Level of Serum IL-17 and Salivary IL-4 in Patients Suffering From Erosive/Atrophic Oral Lichen Planus: A Case Control Study," *Egyptian Journal of Chemistry* 67 (2024), https://doi.org/10.21608/ejchem.2024.296228.9832.

10970347, 0, Downloaded from https://onlinelibrary.wiley.com/doi/10.1002/hed.70012 by City Of Hope - Lee Graff Medic, Wiley Online Library on [26/08/2025]. See the Terms and Conditions (https://onlinelibrary.wiley.com/terms-and-conditions) on Wiley Online Library for rules of use; OA articles are governed by the applicable Creative Commons License