Int J Clin Exp Pathol 2026;19(7):346-351
www.ijcep.com /ISSN:1936-2625/IJCEP0172356

Case Report

Resolution of painful refractory soft palate mucoceles following post-surgical onset of satellite lesions: a rare three-year course

Collin L. Ellis[1], Ankona Ghosh[2], Joel B. Epstein[2,3,4,5]

[1]Allied Health Program, Department of Life Sciences, Santa Monica College, Santa Monica, CA, USA; [2]Department of Head and Neck Surgery, Cedars-Sinai Medical Center, Los Angeles, CA, USA; [3]Samuel Oschin Comprehensive Cancer Institute, Cedars-Sinai Health System, Los Angeles, CA, USA; [4]Dental Oncology Service, Division of Surgery, City of Hope National Medical Center, Duarte, CA, USA; [5]Oral Medicine Pacific of Los Angeles, CA and Vancouver, BC, Canada

Received March 1, 2026; Accepted June 11, 2026; Epub July 15, 2026; Published July 30, 2026

Abstract: Painful refractory mucoceles erupting along the soft palate are uncommon and management pathways are not well established. In general, oral mucoceles represent common non-neoplastic, non-infectious lesions of the minor/accessory salivary glands and are categorized histopathologically as mucus extravasation phenomena or mucus-retention cysts. We report a rare 3-year treatment-resistant course of painful soft palate mucocele clusters in an adult male causing significant impairment in quality of life, affecting speaking, swallowing, and psychological well-being. The case began as two isolated soft palate mucoceles bilateral to the midline. Excision with biopsy and suture closure was performed and resulted in severe satellite lesion development around the operative fields. Histopathology diagnosed salivary gland mucocele, showing extravasated mucin with neutrophils, macrophages, chronically inflamed granulation tissue, and no dysplasia or malignancy. Corrective medical attempts via corticosteroid therapy were followed by black hairy tongue and lingual candidiasis. Revision surgery with electrocautery ablation (no sutures) produced marked yet incomplete lesion reduction. After 3 years of approximately daily lesion eruption, complete resolution for 9 months to date was achieved with off-label use of intralesional and submucosal sclerosant injections combined with electrocauterization and followed by red/near-infrared light therapy (photobiomodulation or PBM). This case highlights an uncommon presentation of chronic painful salivary gland mucoceles on the soft palate with post-surgical onset of satellite lesions. Relatively non-invasive, corticosteroid-free therapies incorporating sclerotherapy with electrocautery and adjunctive PBM could be considered in related cases. To our knowledge, this multimodal approach to a rare presentation has not been previously reported.

Keywords: Salivary gland, oral mucocele, soft palate, sclerotherapy, photobiomodulation

Introduction

Oral mucoceles are common non-neoplastic, non-infectious lesions of the accessory/minor salivary glands and their ducts [1-3]. They usually present as self-limiting fluid-filled vesicles, superficial blisters, or deeper nodules, the latter of which may be more painful. These lesions may be accompanied by erythema, chronic fibrosis, and viscous discharge. Etiology is multifactorial and incompletely understood and recurrence can be common [1-5].

Mucoceles on the soft palate are relatively uncommon, as they typically arise on the lips, cheeks, or tongue, following mechanical disruption of the salivary gland ducts, although extraoral presentations have been reported [3-5]. These lesions are grouped into mucus extravasation phenomena, which lack epithelial lining and reflect ductal disruption with mucin discharge, and mucus-retention cysts, which are true epithelial-lined cysts caused by obstruction [1-5]. Some mucocele cases can be asymptomatic, especially when superficial. Others are painful and bidirectionally associated with psychological stress and foreign-body sensation [1, 3]. Taken together, persistent painful mucoceles involving the soft palate represent an uncommon presentation, with impor-

https://doi.org/10.62347/CDCX4201

tant management implications due to functional anatomy involved in speech and swallowing [2, 3, 5].

Case report

This case began in a 38-year-old immunologically healthy male with two painful retention-type soft palate mucoceles bilateral to the midline which were refractory to CO_2 laser treatment. Lesions were excised with biopsy under local anesthesia, followed by closure with absorbable sutures (**Figure 1A**). Histopathologic analysis confirmed findings consistent with mucoceles [2, 4]. Specifically, pathology demonstrated minor/accessory salivary gland origin with extravasated mucin, neutrophils, macrophages, chronic granulation tissue, and no dysplasia or malignancy (Supplemental File 1).

The mucoceles recurred by postoperative week 2 and, by week 4, clusters of highly symptomatic satellite lesions had erupted in both operative fields, consisting predominantly of extravasation-type with some retention-type mucoceles (**Figure 1B**, **1C**). After months of daily eruption without relief, the patient was told by the prior provider that these lesions were incurable, and they had no further treatment options.

The patient sought acupuncture and herbal medicine with no relief. Infectious, autoimmune, gastroenterological, and allergic etiologies were ruled out. Six months later, the patient was evaluated by otolaryngology/ENT and oral medicine where our initial examination revealed dilated minor salivary glands and inflamed deep nodules elevated several millimeters on the soft palate, with peripheral erythema and occasional bleeding (**Figure 1D**). These lesions caused significant pain with speaking and swallowing solids, liquids, and saliva, with minute-by-minute distress. Relevant family history was denied. The original lesion etiology remains unknown. Patient recalled one lesion erupting throughout childhood, but without associated trauma.

Prior providers had administered a variety of corticosteroid therapies over a 6-month period including topical triamcinolone, fluocinonide, and betamethasone, followed by oral methylprednisolone then a compounded rinse containing methylprednisolone, doxycycline, and nystatin. Despite reported success of corticosteroid-containing regimens in isolated cases of oral mucoceles [6], these were ineffective in our patient and complicated by black hairy tongue with marked elongation of filiform papillae. After corticosteroid discontinuation, black hairy tongue resolved, but was followed by resistant, tongue-localized candidiasis with culture-confirmed *Candida parapsilosis* (**Figure 1E**, **1F**). One-month fluconazole (100 mg/day then 200 mg/day) followed by 1-month high-dose nystatin suspension (10 mL of 100,000 units/mL QID), compounded with non-fermentable stevia instead of sucrose, cleared overgrowth as confirmed by culture.

Isolated intralesional triamcinolone injections were administered primarily for temporary analgesia. Initial clearance occurred, but recurrence followed 1.5 weeks later. Cup-forceps excision with silver nitrate hemostasis produced the same result. Thus, despite known risks to speaking and swallowing, the patient elected revision surgery under general anesthesia. Lesions were excised with overlying mucosa and associated submucosal salivary gland tissue, while preserving underlying musculature (**Figure 1G**). This produced a durable reduction in lesion burden, but isolated lesions recurred along the surgical-site perimeter after approximately 2 months and continued to substantially impair quality of life (**Figure 1H**).

Lidocaine gel was initiated for pain control but became impractical due to interference with speech and swallowing. Lifestyle modifications were attempted: “natural” toothpaste/mouthwash and a soft, non-acidic bland diet were employed. Smoking cessation was not relevant in our patient. Although it did not result in remission, the patient continued a diet trial for 1 year because common foods exacerbated lesion eruption. This resulted in unintentional 17-pound weight loss and hypotension without medication or exercise changes.

Daily painful eruptions continued. The patient resorted to traumatic self-treatment by forcibly rupturing blisters with a hard-bristled mechanical toothbrush, which only provided transient relief until recurrence within 1-2 days and possibly exacerbated eruption. Symptoms were associated with marked distress and sleep disturbances including severe sweating and nightmares related to the lesions. By year 3 of

Figure 1. A-L. Clinic photos across 3 years. A. Two original retention-type mucocele lesions prior to first surgery; B. Two weeks after initial surgery with suture closure; C. Four weeks after initial surgery with suture closure; D. Initial clinic presentation 6 months after prior surgery with suture closure; E. Black hairy tongue associated with prior corticosteroid therapy; F. Lingual candidiasis associated with prior corticosteroid therapy; G. Operative fields after revision surgery with electrocautery ablation (no sutures); H. Refractory lesions 2 months after revision surgery; I. Wound healing 1 week after sclerotherapy with electrocautery; J. Use of photobiomodulation (light therapy) device at 90 seconds BID; K. Handheld light therapy device with fiber optic probe adaptor; L. Lesion resolution with only fibrous scar tissue remaining at 9 months; accompanied by residual sensory neuropathic symptoms.

painful disease and repeated interventions, the ongoing burden substantially affected the patient's physical and mental well-being personally and professionally. Pain-management counseling was initiated while final options were explored.

Based on reports of relatively non-invasive, off-label sclerotherapy for oral mucoceles [7, 8], we combined sclerotherapy with electrocauterization. After marsupialization and electrocautery ablation, the sclerosing agent was injected intralesionally and submucosally via a 30G needle. Wound healing took approximately 2 weeks (**Figure 1I**). Sclerosant preparation included 1 cc of 3% sodium tetradecyl sulfate (STS) diluted 1:1 with sterile saline [8].

After two unsuccessful treatment trials, with all lesions recurring at approximately week 2, a third and final trial was supplemented with photobiomodulation (PBM), also known as low-level laser therapy, based on recent applications in other mucosal conditions [9, 10]. PBM was administered BID for 90 seconds to each lesion mass using a dual-wavelength handheld device stated to deliver red (650 nm) and near-infrared (850 nm) light at over 1 joule/sec on high mode (8 Hz). Light was applied by direct lesion contact using a fiber-optic probe adaptor stated to multiply output by 12× to isolate and deepen delivery (**Figure 1J**, **1K**). After 2 weeks of PBM following the third sclerotherapy treatment, lesions did not recur as before. The patient remains clear to date and reports continued daily PBM self-treatment.

At writing, despite over 3 years of approximately daily eruptions, the patient remained lesion-free at 1-, 2-, 3-, 6-, and 9-month follow-up, and only fibrous scar tissue remains (**Figure 1L**). Although some residual sensory neuropathic symptoms persist, particularly during prolonged speaking, the patient resumed a normal diet, regained all lost weight, became normotensive, reports improved sleep with significantly fewer nightmares and episodes of nocturnal hyperhidrosis, and describes a substantial return to baseline physical and psychological well-being.

Discussion

Painful, refractory soft palate mucoceles persisting for several years in otherwise healthy adults are rare [2, 3, 5, 6]. Although mucoceles are often asymptomatic, selected cases can substantially impair quality of life [6]. In this patient, chronic pain with speaking and swallowing may have reflected pressure on CNV2 sensory endings and local inflammatory irritation from the ulcerations and erosions left upon lesion rupture.

We report complete resolution sustained for 9 months to date after 3 years of nearly daily eruptions, despite intermittent, spatially distinct appearances of three painless small lesions that appeared/disappeared over 48 hours (**Figure 2**). The refractory mucoceles were first markedly reduced by revision surgery using scalpel excision followed by electrocautery ablation of the surgical bed. This approach was selected because prior suture closure was suspected to contribute to new satellite lesions after initial excision, possibly through additional ductal disruption and/or entrapment of residual glandular units under tension, mechanisms consistent with mucocele pathogenesis [1-3]. The durable reduction in lesion burden after revision surgery may reflect more complete elimination of disrupted minor salivary gland tissue, thereby reducing ongoing mucin extravasation, consistent with pathogenesis and recurrence behavior [2-5]. However, this remains speculative because comparative mechanistic studies are lacking.

Because lesions refractory to revision surgery remained highly painful, STS sclerotherapy [8] was attempted immediately following electrocautery. After two failed rounds, 90 seconds BID of red/near-infrared PBM was employed following the third and final round, providing complete resolution to date. Based on treatment sequence and temporal association, PBM is postulated to have contributed to this outcome. Whether original pre-surgery lesions could have been resolved with PBM alone, or with sclerosant injections, is unknown. Off-label sclerotherapy and PBM have been used for mucosal lesions [7-10]. PBM is hypothesized to modulate cellular activity through non-thermal light-tissue interactions, with reported effects on tissue repair, inflammation, and pain modulation [9, 10], providing a biological rationale for the improvement observed.

Causality cannot be established, and treatment recommendations cannot be drawn from one case. We also cannot determine the inde-

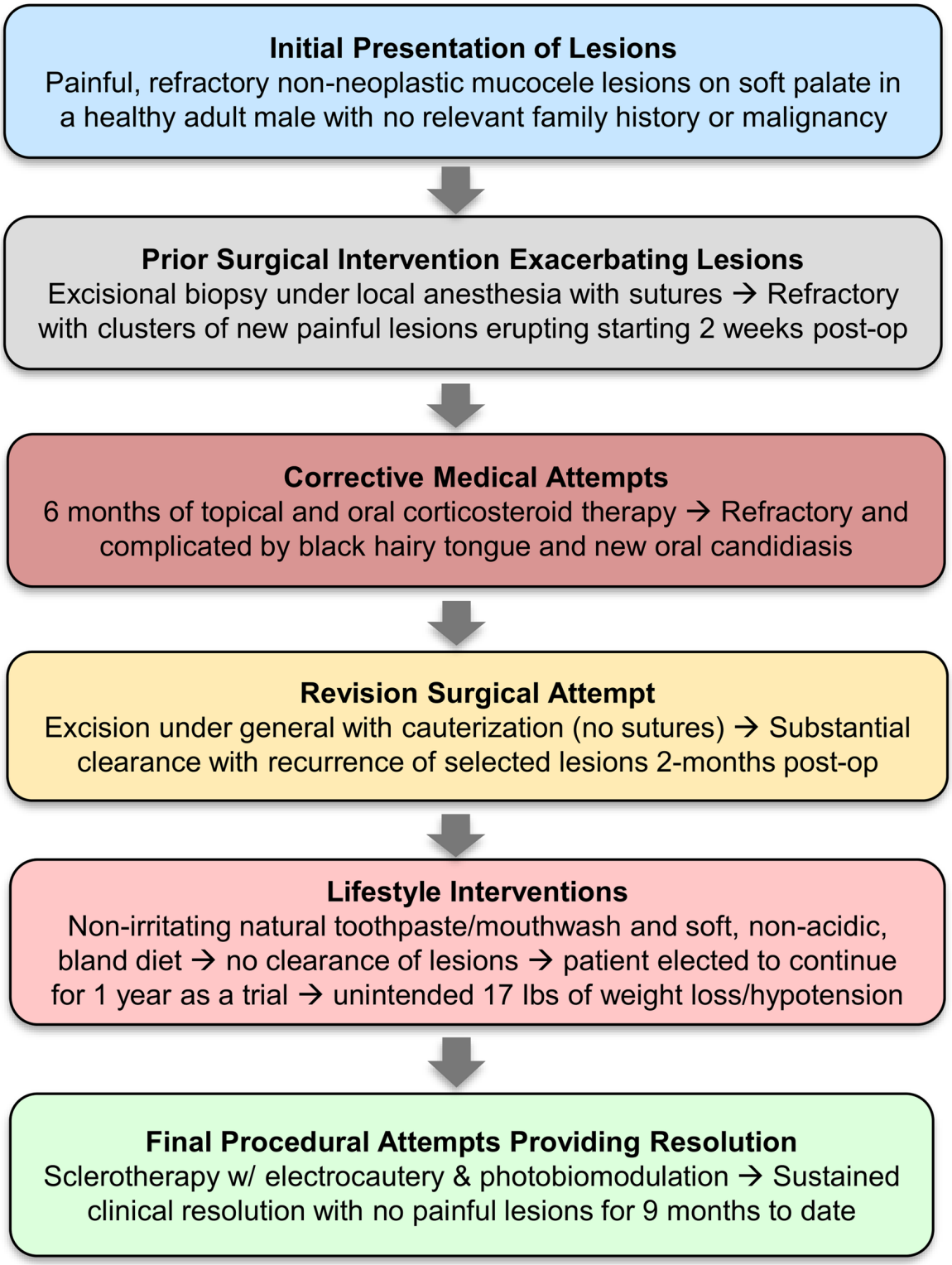

Figure 2. Clinical course and treatment timeline across 3 years.

pendent contribution of PBM relative to sclerotherapy with electrocautery because these interventions were combined in the final trial. Controlled multi-patient studies are required to determine whether the effects of these modalities are isolated or synergistic.

Conclusion

Given the favorable outcome, off-label sclerotherapy with electrocautery and adjunctive PBM may be considered for painful chronic mucoceles, including before more invasive surgical interventions and in refractory cases where conventional treatments fail or are poorly tolerated. The morbidity of oral mucoceles can be underappreciated because some oral-site lesions are asymptomatic. Moreover, misperceptions communicated to patients that these lesions are incurable can exacerbate despondency. Our patient reported severe emotional/psychological distress from these painful, functionally impairing lesions, compounded by prior communication that the condition was permanent. This underscores the importance of careful counseling, avoiding overly definitive statements regarding incurability, and thorough exploration of feasible therapies in chronic refractory disease.

Disclosure of conflict of interest

Author J.B.E. reports research funding from SaNOtize Research and MeiraGTx Holdings (unrelated to this work) and consultancy with Photonic Therapy Institute which provided the light therapy device that was used by the patient. Authors C.L.E. and A.G. have nothing to report.

Address correspondence to: Collin L. Ellis, Allied Health Program, Department of Life Sciences, Santa Monica College, 1900 Pico Blvd., Santa Monica, CA 90405-1628, USA. Tel: 310-434-8279; E-mail: ellis_collin@smc.edu

References

[1] Jani DR, Chawda J, Sundaragiri SK and Parmar G. Mucocele--a study of 36 cases. Indian J Dent Res 2010; 21: 337-40.

[2] Hayashida AM, Zerbinatti DC, Balducci I, Cabral LA and Almeida JD. Mucus extravasation and retention phenomena: a 24-year study. BMC Oral Health 2010; 10: 15.

[3] More CB, Bhavsar K, Varma S and Tailo M. Oral mucocele: a clinical and histopathological study. J Oral Maxillofac Pathol 2014; 18 Suppl 1: S72-S77.

[4] Choi YJ, Byun JS, Choi JK and Jung JK. Identification of predictive variables for the recurrence of oral mucocele. Med Oral Patol Oral Cir Bucal 2019; 24: e231-235.

[5] Chi AC, Lambert PR 3rd, Richardson MS and Neville BW. Oral mucoceles: a clinicopathologic review of 1,824 cases, including unusual variants. J Oral Maxillofac Surg 2011; 69: 1086-93.

[6] Wang J, Lin F, Liu Y and Guan X. Effective treatment of multiple oral mucoceles. Int J Oral Maxillofac Surg 2025; 54: 1182-1186.

[7] Huang Y, Yang C, Wang T, Liu S and Chen A. Preliminary experience with promethazine hydrochloride injection in the sclerotherapy of oral mucocele. Int J Oral Maxillofac Surg 2021; 50: 516-521.

[8] Gaikwad TV, Maini AP, Das S, Lokhande S, Patil SK and Sarma A. Nonsurgical management of oral mucocele occurring on a rare site. Contemp Clin Dent 2022; 13: 389-391.

[9] Dompe C, Moncrieff L, Matys J, Grzech-Leśniak K, Kocherova I, Bryja A, Bruska M, Dominiak M, Mozdziak P, Skiba THI, Shibli JA, Angelova Volponi A, Kempisty B and Dyszkiewicz-Konwińska M. Photobiomodulation-underlying mechanism and clinical applications. J Clin Med 2020; 9: 1724.

[10] Epstein JB, Raber-Durlacher JE, Epstein GL, Hazenberg MD, Tzachanis D and Spielberger RT. Chronic oral graft-versus-host disease: induction and maintenance therapy with photobiomodulation. Support Care Cancer 2021; 29: 1387-1394.